



PAPER ID: 11A14H



## MORPHOLOGICAL STUDIES IN THE TREATMENT OF EXPERIMENTAL BURN INJURIES OF THE SECOND AND THIRD DEGREES IN DOGS

T.N. Shnyakina<sup>1</sup>, N.M. Bezina<sup>1</sup>, N.P. Shcherbakov<sup>2</sup>, L.V. Chernyshova<sup>3</sup>,  
T.N. Makarova<sup>3\*</sup>, I.R. Kanagina<sup>3</sup>, L.V. Medvedeva<sup>4</sup>

<sup>1</sup> Department of Infectious Diseases and Veterinary and Sanitary Expertise, South Ural State Agrarian University, Troitsk, RUSSIA.

<sup>2</sup> Innovation Research Center, South Ural State Agrarian University, Troitsk, RUSSIA.

<sup>3</sup> Department of Biology, Ecology, Genetics and Animal Breeding, South Ural State Agrarian University, Troitsk, RUSSIA.

<sup>4</sup> Faculty of Veterinary Medicine, Altai State Agrarian University, Barnaul, RUSSIA.

### ARTICLE INFO

#### Article history:

Received 06 March 2020  
Received in revised form 10 June 2020  
Accepted 20 July 2020  
Available online 10 August 2020

#### Keywords:

Dermis; Thermal burns;  
Inflammation reaction;  
Necrosis;  
Pharmacological mixture;  
Morphological studies;  
Regeneration;  
Granulation tissue.

### ABSTRACT

The article presents the results of morphological studies of an effectiveness method in treatment of burn injuries in dogs using pharmacological mixtures (iodinol-chlorophyllipt solution and vinylin-salicylic liniment), taking into account the phase of the wound process. The composition of the iodinol-chlorophylliptic solution includes iodinol, novocaine, a 1% alcohol solution of chlorophyllipt (diluted 1:5 with distilled water) and dimexide. The composition of the vinylin-salicylic liniment includes salicylic acid, vinylin, a 1% alcohol solution of chlorophyllipt (diluted 1:5 with distilled water) and lavender oil. In the first phase of the wound healing process for the treatment of burns in animals of experimental group No. 2, dressings were used, soaked in iodinol-chlorophylliptic solution, and in the second phase of the wound healing process, a vinylin-salicylic liniment was applied to the burn wound. Morphological studies of burnt tissues showed that in both experimental groups in the early stages of observation, the severity of the exudative phase of the inflammatory reaction is less pronounced than in the control group; the number of macrophages, is higher especially in the experimental group No.2. By the 21st day in experimental group No.2, the specific areas of newly formed collagen fibers and blood vessels with significantly lower cellularity of the infiltrate were greater, which indicates earlier maturation of granulation tissue. From the results, the regeneration of damaged tissues in animals of experimental group No.2 occurred with a predominance of reparative processes.

**Disciplinary:** Biological Science, Veterinary Medicine, Biotechnology.

©2020 INT TRANS J ENG MANAG SCI TECH.

## 1 INTRODUCTION

Burns in developed countries are one of the most common types of widespread damage (Sokolov et al., 2015; Spurr et al., 1990). According to the World Health Organization, burns take the third place among injuries, and in some countries, for example, Japan, thesecond place, thesecond only to transport injury, while the number of injured in industrialized countries is constantly growing (Jacob et al., 2017; Shnyakina and Bezina, 2017). More than 800 thousand cases of burns of varying severity are registered in Russia annually, and their frequency is 300-350 cases per 10 thousand of the population (Luengo-Pastor et al., 2019).

Today, despite the successes achieved in the treatment of burns and their consequences, mortality among victims remains high (Vyas and Wong, 2013). This is due to the development of pain shock and the occurrence of burn toxemia, as well as the multiplication of pathogenic microflora on the surface of burn wounds (Benchamkha et al., 2017). Many methods have been proposed for treating burns in animals, but all of them have a number of disadvantages. Plastic surgery is sometimes impossible due to the complexity of the operation, if not to mention the often observed cases of complete rejection of the transplanted skin flap. Therefore, conservative treatment of burn wounds remains relevant (Kaddoura et al., 2017).

For local treatment of thermal burns in animals, we have proposed two pharmacological mixtures (iodinol-chlorophylliptic solution and vinylin-salicylic liniment), compiled taking into account the peculiarities of the wound process in burn injuries. The composition of the iodinol-chlorophylliptic solution includes iodinol, novocaine, a 1% alcohol solution of chlorophyllipt (diluted 1: 5 with distilled water) and dimexide. The composition of the vinylin-salicylic liniment includes salicylic acid, vinylin, a 1% alcohol solution of chlorophyllipt (diluted 1: 5 with distilled water) and lavender oil. The components for the mixtures were purchased at a retail pharmacy chain. The components were mixed in the laboratory of the Chair of Infectious Diseases of the Federal State Budget Educational Establishment of Higher Education in the South Ural State Agrarian University. The components for the pharmacological mixtures were selected taking into account their pharmacological properties, as well as the characteristics of the course of the wound process in case of burns.

The study proposes an effectiveness method for the treatment of burn wounds in animals, as well as its effect on morphological indicators in dogs with experimental burns.

## 2 CONDITIONS, MATERIALS AND RESEARCH METHODS

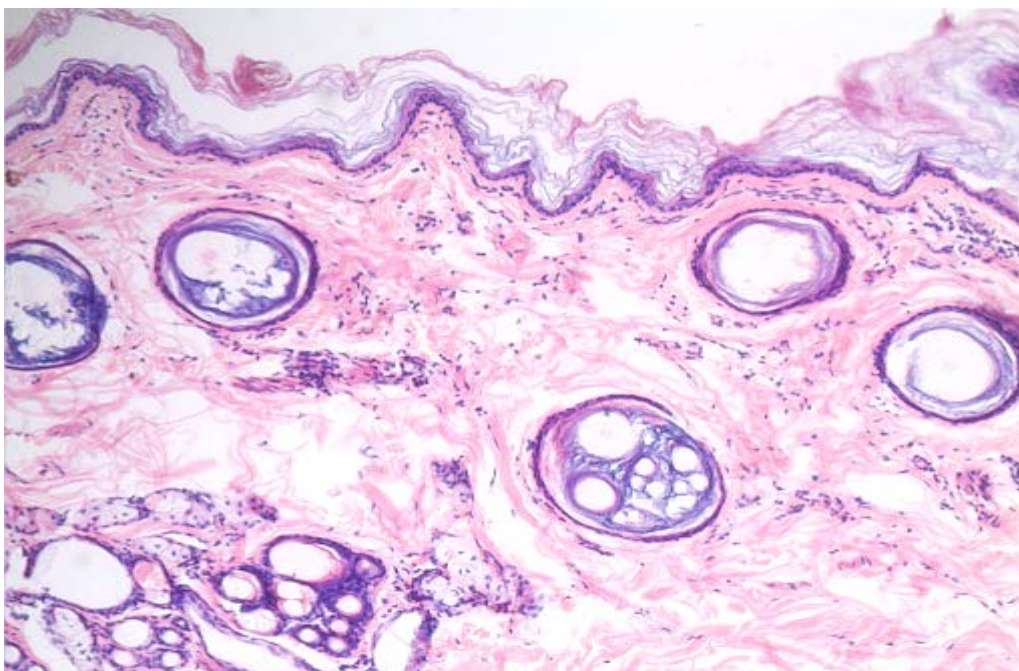
An experimental study was conducted on 15 dogs, which were divided into 3 groups: control, experimental group No.1 and experimental group No.2. On the lateral thigh surface, of sogsexperimental modeling of burns was performed according to the method of Kalashnik (2014). Infiltration anesthesia was applied by subcutaneous administration of a 0.5% solution of novocaine at a dose of 3 ml<sup>3</sup>. Work with animals was carried out taking into account the standards of the Ethics Committee and the requirements of bioethical norms. The formation of burns of the II<sup>nd</sup> and III<sup>rd</sup> degree was revealed on the lateral thigh surface of dogs in 24 hours. Starting from the second day, the animals of the control group were treated twice daily with ointment levomekol; animals of the experimental group No.1 with 1% alcohol solution of chlorophyllipt (diluted 1:5 with distilled water);

animals of the experimental group No.2 with iodinol-chlorophylliptic solution (2-4 days), then, after of exudative processes stopped, vinylin-salicylic liniment was applied the same way. For the treatment of animals of experimental group No.2 in the first phase of the wound process during the exudation stage (2-4 days) in order to reduce the traumatic effect on damaged tissues, as well as to prevent microbial contamination of the burn wound, a dressing method was used applying wet drying suction dressings soaked in iodinol-chlorophylliptic solution. In order to avoid independent removal of the bandage, the animals were put on a protective collar. After the completion of exudative processes, in the second phase of the wound healing process, starting from the 5th day, a vinylin-salicylic liniment was applied twice daily on a burn wound in animals of experimental group No.2 without applying a bandage.

In order to identify morphological changes in burnt tissues, a histological examination was performed. Moreover, in the course of surgical treatment, animals were excised from tissue pieces and fixed in a 10% formalin solution. Material was poured with celloidin. Serial celloidin sections were stained with hematoxylin-eosin, van Giesonpicrofuchsin and Schiff's reagent. Histological preparations were studied on a LEICA DMRXA microscope (Germany). Using a digital video camera LEICA DFC 290 (Germany), coupled with a personal computer, images of micropreparations were obtained in the format of TIFF graphic files in the RGB color space. For morphometric studies, ImageScope M (Germany) image analysis software was used.

### 3 RESEARCH RESULTS AND DISCUSSION

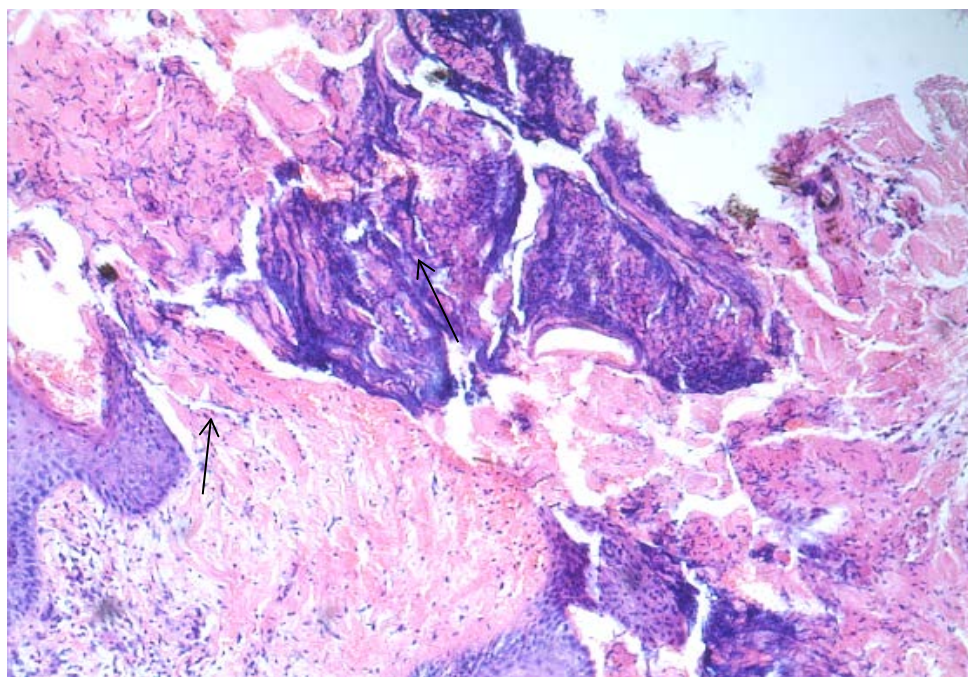
To conduct histological studies to reveal morphological changes in burnt tissues of animals of the control and experimental groups, pieces of tissue were excised during the surgical treatment on the 7th, 14th, and 21st days.



**Figure 1:** Morphological changes in the skin of the animal of the control group on the 7th day of the experiment (overview photo of the skin with a thin horny layer, HE X 50, color (hematoxylin-eosin))

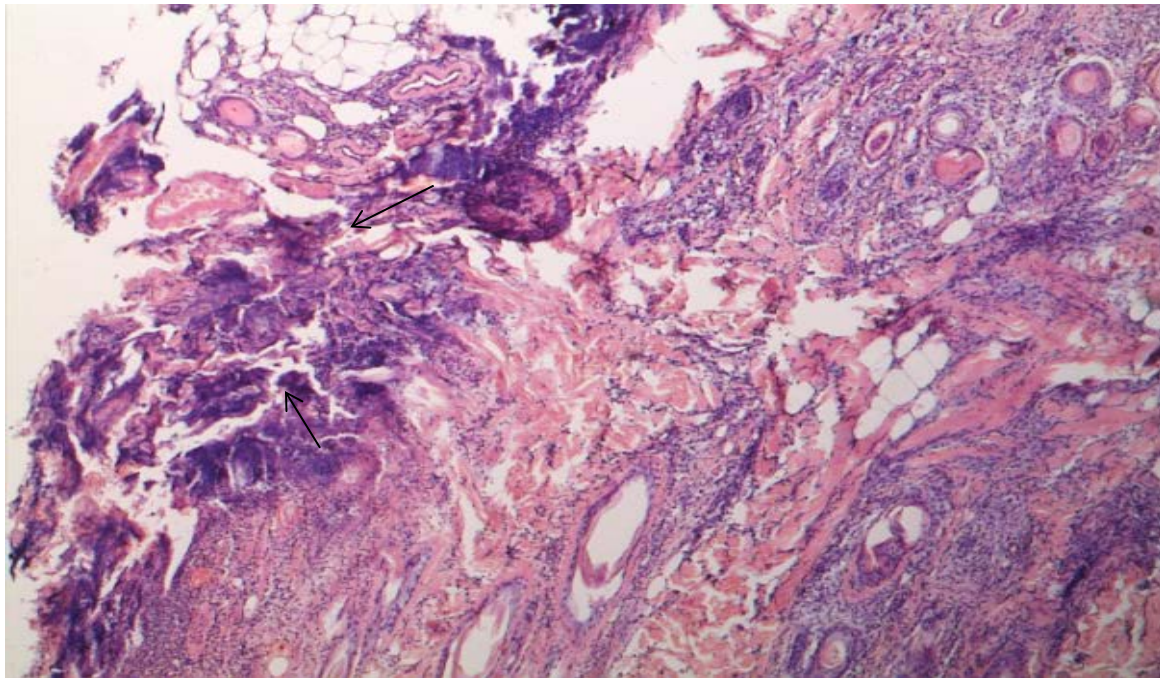


In Figure 1, the epidermis and stratum corneum are present in all fields of view. In all layers of the skin, there is a venous and capillary plethora. The dermal papillae are equally pronounced throughout the section, except for a small area along the edge of the preparation, where the thickening of the epidermal layer is visible due to the proliferation of the basal layer of cells and the manifestations of acanthosis are expressed. In the reticular layer of the dermis in this area, there are perivascular neutrophilic lymphocytic infiltrates with spreading phenomena along with the stroma. Collagen fibers here are loosened, separated by serous exudate mixed with a small number of macrophages and plasma cells. Schiff's reagent staining reveals SIC-positive structures only in the region of the basement membrane. There are no positive inclusions in the cytoplasm of epidermocytes CHIC.



**Figure 2:** Morphological changes in the skin of an animal of experimental group No.1 on the 7th day of the experiment, HE X 50, color (hematoxylin-eosin)

In Figure 2, in the area that occupies several fields of view, the focus of necrosis is determined, including the epidermis, papillary, and reticular dermis. In the area of necrosis, a “fixing” effect of high temperatures can be traced: all structural identification elements of the dermis, including the connective tissue matrix, vessels, and skin appendages, are well visualized. Necrotic tissues are optically dense, with an intense basophilic hue. At high magnification, a reorientation of the nuclei of the cells of the sebaceous glands and vascular endothelium is visible in the form of “panicles” and “brushes”. In the perifocal zones, there is a perivascular venous and capillary plethora with a picture of leukostasis and the formation of perivascular muft-like neutrophilic lymphocytic infiltrates. The site of necrosis is delimited from intact tissues by the cell shaft, consisting mainly of decaying neutrophilic leukocytes mixed with lymphoid cells and macrophages. Among inflammatory exudate cells, strands and bundles of proliferating spindle-shaped fibroblasts are visible. In the area of the perifocal shaft, multiple thin convoluted randomly located collagen fibers are determined. In the epidermal layer, at the border of the focus of necrosis and intact tissues, keratinocyte proliferation processes are recorded: enlarged cells in the basal and prickly layers contain a large number of glycogen grains in the cytoplasm.



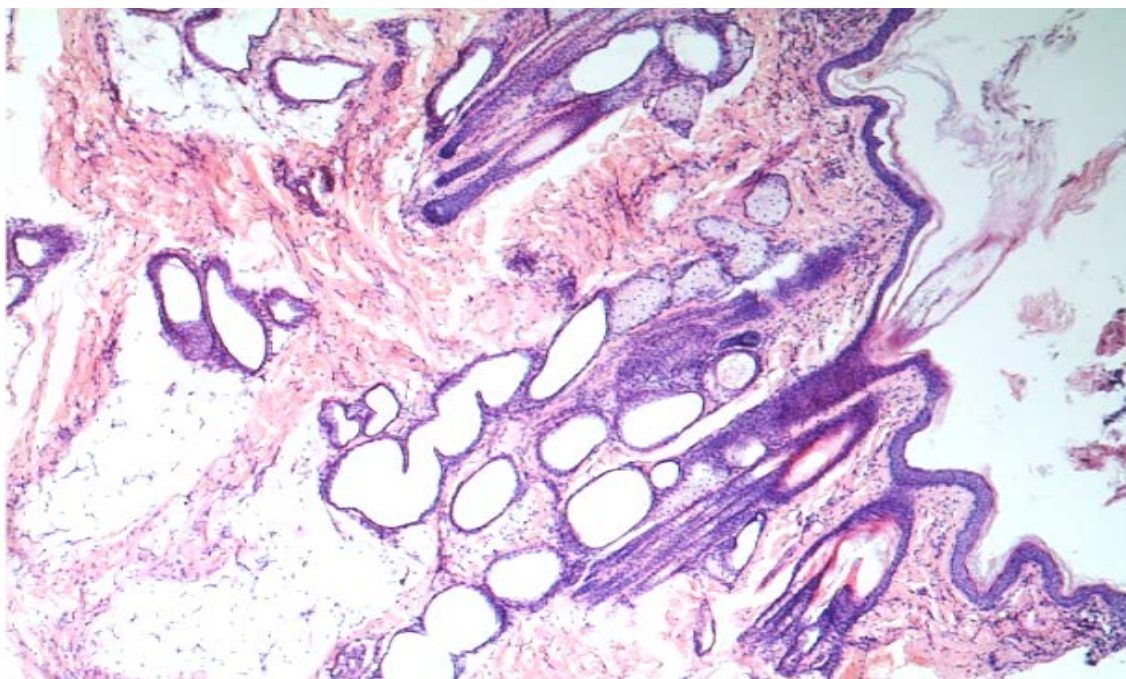
**Figure 3:** Morphological changes in the skin of an animal of experimental group No.2 on the 7th day of the experiment, HE X 50, color (hematoxylin-eosin)

In Figure 3, in the area that occupies several fields of view, the focus of necrosis is determined, including the epidermis, papillary and reticular layers of the dermis, sometimes with the capture of the hypodermis. In the area of necrosis, a “fixing” effect of high temperatures can be traced: all structural identification elements of the dermis, including the connective tissue matrix, vessels, and skin appendages, are well visualized. Necrotic tissues are optically dense, with an intense basophilic hue. At high magnification under, a reorientation of the nuclei of the cells of the sebaceous glands and vascular endothelium is visible in the form of figures of “panicles” and “brushes”. In the perifocal zones, there is a paretic venous and capillary plethora with a picture of leuko and erythrocytoses and red blood cell slimming. The site of necrosis is delimited from intact tissues by a shaft of decaying neutrophilic leukocytes mixed with lymphoid cells and macrophages. In the perifocal zone, the proliferation sites of young fibroblasts and the initial phenomena of fibrillogenesis are visible: when Van Gieson stains picrofuchsin with accumulations of young fibroblasts, numerous thin convoluted randomly arranged collagen fibers are visible. In the epidermal layer, at the border of the focus of necrosis and intact tissues, keratinocyte proliferation processes are recorded: enlarged cells in the basal and prickly layers contain a large number of glycogen grains in the cytoplasm.

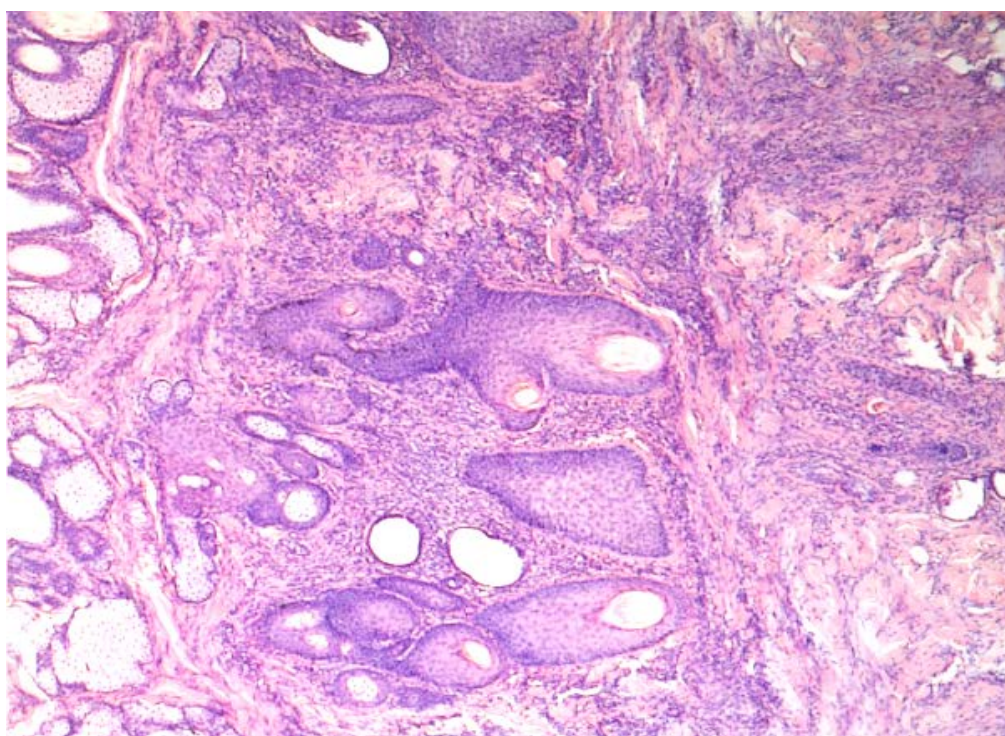
In Figure 4, the epidermis and stratum corneum are present in all fields of view. The papilla of the dermis is equally well pronounced throughout the cut. In all layers of the skin, there is a paretic venous and capillary plethora with a picture of red blood cells and red blood cell counting. In the reticular layer of the dermis, there is a weak neutrophilic lymphocytic infiltration with the phenomena of decay of leukocytes. In the hypodermis on a site that occupies several fields of vision, a focus of necrosis is defined, delimited from intact tissue by a layer of immature granulation tissue rich in cellular elements, newly formed connective tissue fibers and vessels. Young proliferating fibroblasts predominate in the cellular composition. There are also quite extensive foci of neutrophilic lymphocytic infiltration and macrophage proliferation sites mixed with a small number of plasma



cells. Newly formed collagen fibers are slightly twisted, short, thick. Newly formed vessels have differentiated walls and endothelial lining, their lumens are filled with blood. A small number of glycogen grains are detected in the epidermis.



**Figure 4:** Morphological changes in the skin of an animal control group on the 14th day of the experiment, HE X 50, color (hematoxylin-eosin)



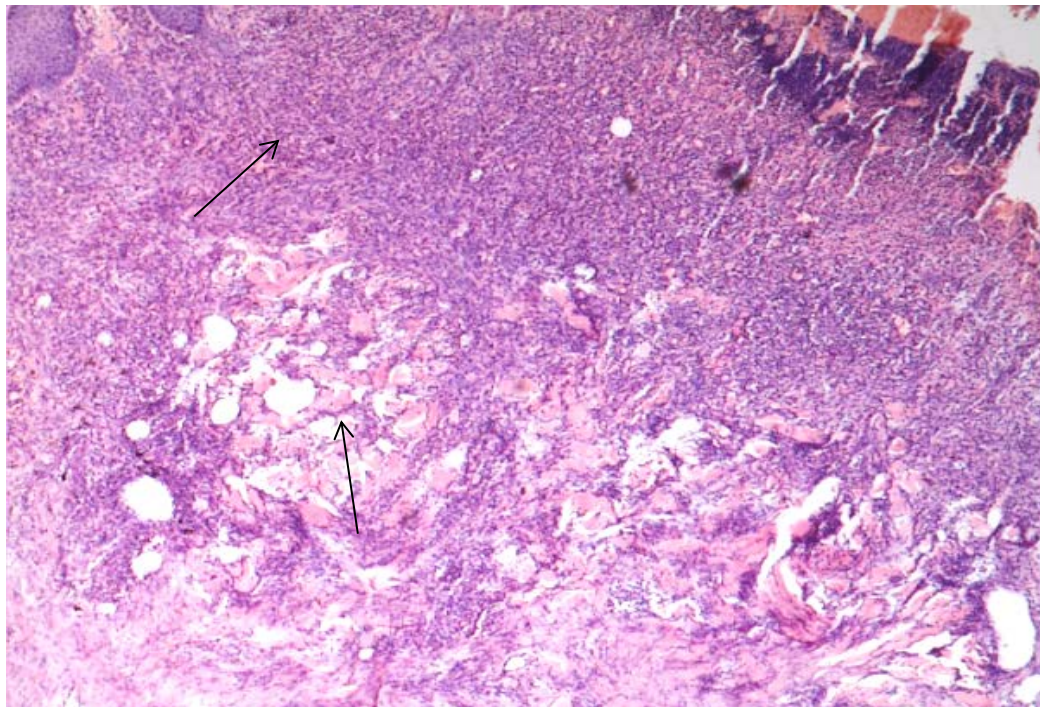
**Figure 5:** Morphological changes in the skin of an animal experimental group No.1 on the 14-day experience, HE X 50, color (hematoxylin-eosin)

In Figure 5, fragments of a stratified squamous keratinized epithelium, papillary and reticular dermis, skin appendages, and fragments of the hypodermis. In the area that occupies several fields of



vision, the locus of replacing the tissue of the papillary and reticular layers of the skin with a young granulation tissue rich in cellular elements, newly formed vessels, and connective tissue fibers is determined. Young forms of fibroblasts predominate in the cellular composition; small foci of macrophage and round-cell infiltration are found. Most newly formed vessels have differentiated walls, their gaps are filled with blood. The newly formed collagenous fibers are thin crimped randomly arranged. Some keratinocytes of the basal and spiky layers contain eccentrically located glycogen grains.

In Figure 6, in the area that occupies several fields of vision, the focus of necrosis is determined, extending inward from the skin surface, down to the reticular dermis. Necrotic tissue has a pronounced basophilic hue and is represented by fine-grained, structureless masses without preserved identification elements. The focus of necrosis is delimited from intact tissues by a layer of young granulation tissue rich in cellular elements, newly formed vessels, and connective tissue fibers.



**Figure 6:** Morphological changes in the skin of an animal of experimental group No.2 on the 14th day of the experiment, HE X 50, color (hematoxylin-eosin)

In the cellular composition, young forms of fibroblasts predominate, foci of macrophage and round-cell infiltration remain. All newly formed vessels have differentiated walls and an endothelial lining, their gaps are filled with blood.

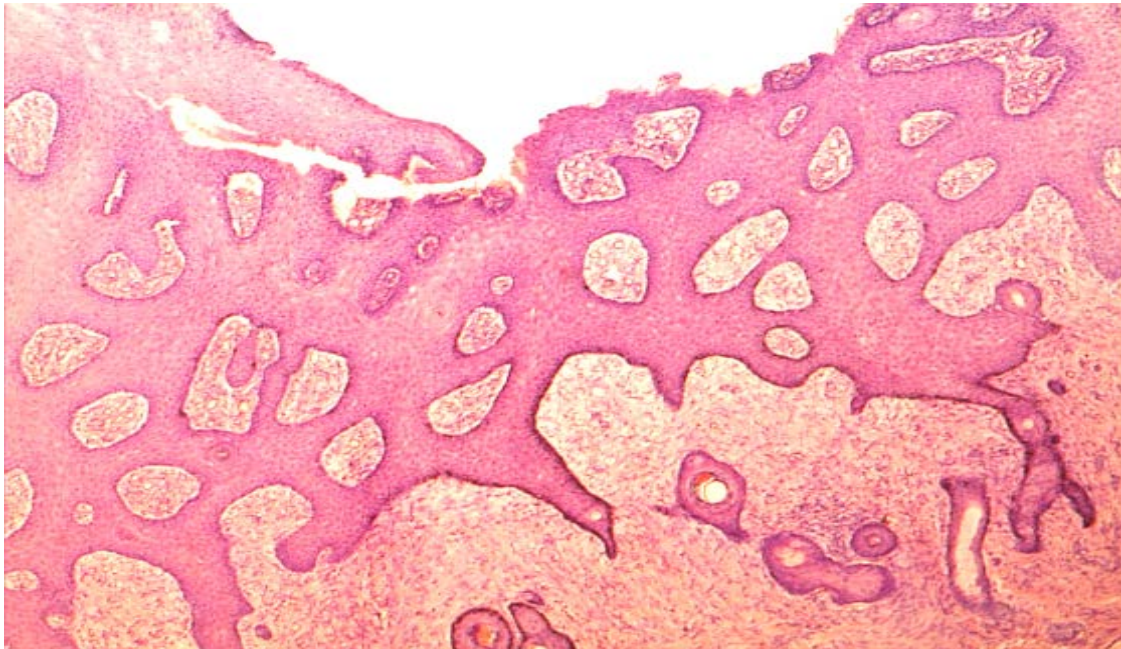
The newly formed collagen fibers are thin, with a tendency to come closer together and merge into larger conglomerates. From the intact skin, the ingrowth of the epidermal layer along the necrotic masses is visible. In this area, keratinocytes of the basal and spiky layers contain brightly colored, eccentrically located glycogen grains.

In the preparation in Figure 7, the epidermis and stratum corneum are present in all fields of vision. At one of their sites, the field of the pronounced proliferation of cells of the basal and spiky layers of the epidermis (acanthosis) with the presence of a large number of glycogen granules in the



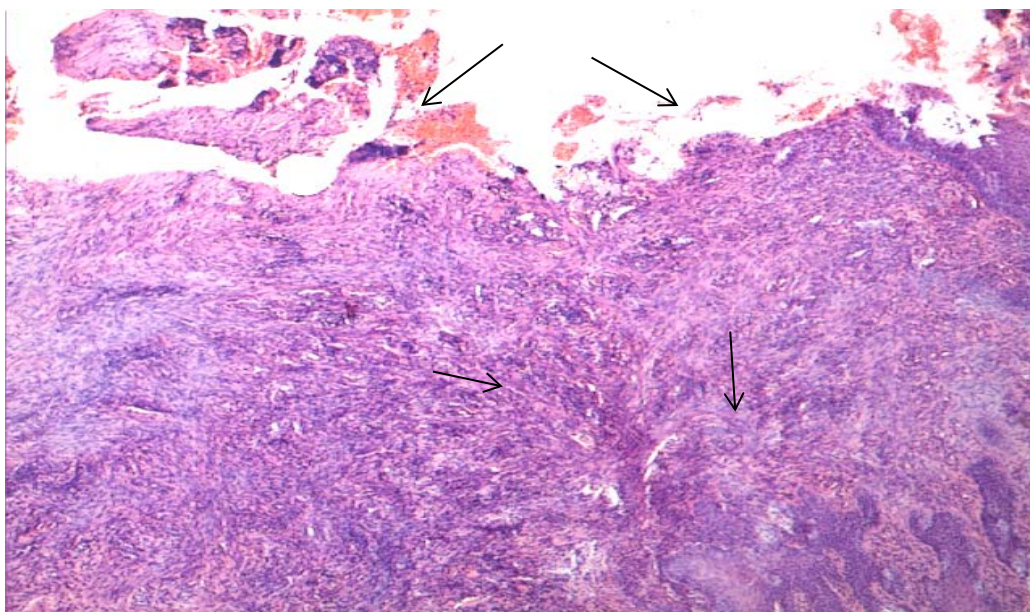
cytoplasm is determined.

In all layers of the skin, there is a venous and capillary plethora, moderate swelling of the interstitial tissue. In the reticular layer of the dermis, there are small diffusely scattered neutrophilic lymphocytic infiltrations.



**Figure 7:** Morphological changes in the skin of an animal control group on the 21st day, HE X 50, color (hematoxylin-eosin)

Collagen fibers are loosened, slightly swollen, and homogenized. In the hypodermis, a fragment of young granulation tissue rich in connective tissue fibers and blood vessels is determined in a limited area. Spindle-shaped fibroblasts predominate in the cellular composition; small clusters of lymphoid cells with an admixture of macrophages are visible.

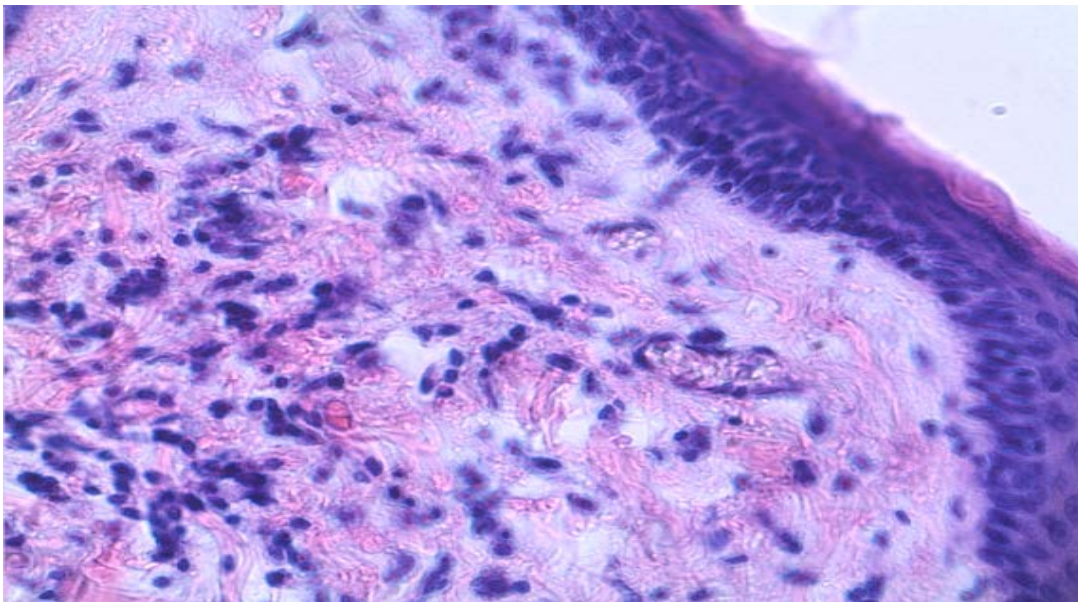


**Figure 8:** Morphological changes in the skin of the animal of experimental group No.1 on the 21st day, HE X 50, color (hematoxylin-eosin)



In the preparation in Figure 8, a small focus of necrosis in the surface layers of the dermis is determined. Necrotic tissues are delimited from the underlying reticular layer of the dermis by a layer of young granulation tissue with a predominance of fibrillar structures over cellular ones. Young spindle-shaped fibroblasts of granulation tissue form bundles and cords that spread in different directions, randomly. Small foci of neutrophilic lymphocytic and macrophage infiltration remain.

The newly formed collagen fibers are crimped, rather thick, folded into disordered bundles. The vessels of granulation tissue have an endothelial lining and differentiated walls, filled with blood. In the epidermis at the border with the focus of necrosis, there are phenomena of the pronounced proliferation of cells of the basal and prickly layers with the presence of a large number of glycogen granules in the cytoplasm.



**Figure 9:** Morphological changes in the skin of an animal experimental group No.2 on the 21st day, HE X 50, color (hematoxylin-eosin)

In the preparation in Figure 9, an epithelized scar is determined. The dermal papillae are smoothed, connective tissue fibers are brought together, folded into compact bundles oriented parallel to the skin surface.

In the cellular composition, young spindle-shaped fibroblasts predominate, forming cell strands and bundles, oriented in the same way as newly formed collagen fibers. Small foci of neutrophilic lymphocytic and macrophage infiltration remain. All vessels of young connective tissue have an endothelial lining and differentiated walls, filled with blood. The cytoplasm of keratinocytes above the connective tissue scar contains a moderate amount of glycogen granules.

## 4 CONCLUSION

Multicomponent mixtures created based on finished preparations: iodinol-chlorophylliptic

mixture and vinylin-salicylic mixture, which we proposed for the treatment of thermal burns, promote activation of regenerative processes in damaged tissues and shorten healing time. When conducting histological studies, it was revealed that the regeneration of damaged tissues in animals during treatment with multicomponent mixtures occurs with a predominance of reparative processes.

Morphological studies of burnt tissues showed that in both experimental groups in the early stages of observation, the severity of the exudative phase of the inflammatory reaction is less than in the control group; the number of macrophages, is higher especially in the experimental group No.2. From modern literature, it is known that the early appearance of macrophages in wounds promotes the simultaneous growth of capillaries and fibroblasts and the differentiation of fibroblasts due to the isolation of several cytokines. This process is especially pronounced in experimental group No.2, which indirectly testified to an earlier start of the processes of collagenogenesis, neoangiogenesis, and wound epithelization, which we observed in the subsequent periods of the experiment.

It should be noted that by the 21st day in the experimental group No.2 there were more specific areas of newly formed collagen fibers and blood vessels with significantly less “cellularity” of the infiltrate, which indicates an earlier maturation of granulation tissue.

## 5 AVAILABILITY OF DATA AND MATERIAL

Information can be made available by contacting the corresponding author.

## 6 REFERENCES

- Benchamkha, Y., Dhaidah, O., Dahazze, A., Meriem, Q., Elamrani, M.D., and Ettalbi, S. (2017). The bacteriological profile of the burned patients in the center of burns in CHU Mohamed VI Marrakech (about 123 cases). *J. Burns Trauma*, 7(6), 72-79.
- Jacob S., Herndon, D.N., Hawkins, H.K., Enkhbaatar, P., and Cox, R.A. (2017). Xanthine oxidase contributes to sustained airway epithelial oxidative stress after scald burn. *J. Burns Trauma*, 7(6), 98-106.
- Luengo-Pastor, M., Guerrero-Dominguez, R., Navarro Suavarro-Suarez, E., Rasero-Moreno, C. (2019). Intervention to reduce pain in patients with superficial and intermediate second degree burns. *Rev Esp Anesthesiol Reanim*, 66, 172-173. DOI: 10.1016/j.redar.2018.12.001
- Kaddoura, I., Abu-Sittah, G., Karamanoukian, R., Papazian, N. (2017). Burn injury: a review of pathophysiology and therapeutic modalities in major burns. *Ann Burns Fire Disasters*, 30(2), 95-102.
- Shnyakina, T.N., Bezina, N.M. (2017). An experimental method for treating burn injury in dogs. Innovative activity in the modernization of the agro-industrial complex: *International scientific-practical conference of students, post-graduate students and young scientists*, Kursk State Agricultural Academy, 278-281.
- Sokolov, V.A., Efimenko, N.A., Admakin, A.L., Petrachkov, S.A., & Stepanchenko, A.A. (2015). Piecetime burns. Sources of danger. *Klinicheskaiia meditsina*, 93(6), 30-35.
- Spurr, E.D., & Shakespeare, P.G. (1990). Incidence of hypertrophic scarring in burn-injured children. *Burns*, 16(3), 179-181.



Vyas, K.S., Wong, L.K. (2013). Oral rehydration solutions for burn management in the field and underdeveloped regions: a review. *Int. J. Burns Trauma*, 3(3), 130-136.

---



**Professor Dr. Shnyakina Tatyana Nikolaevna** is of the Department of Infectious Diseases and Veterinary and Sanitary Expertise, South Ural State Agrarian University. She holds a Doctor of Veterinary Sciences. She is involved in Veterinary Surgery.



**Bezina Nina Mikhailovna** is an Associate Professor of the Department of Infectious Diseases and Veterinary and Sanitary Expertise, South Ural State Agrarian University. She is a Candidate of Veterinary Sciences. Her work deals with Veterinary Surgery



**Professor Dr. Shcherbakov Nikolay Pavlovich** is a Consultant Professor at the Innovation Research Center of the South Ural State Agrarian University. He holds a Doctor of Veterinary Sciences. His works deal with Veterinary Surgery.



**Chernyshova Larisa Vladimirovna** is an Associate Professor of the Department of Biology, Ecology, Genetics and Animal Breeding, South Ural State Agrarian University. She is a Candidate of Biological Sciences. Her works involve Safety and Food Hygiene, Physiological Features of Young Farm Animals, Natural Resources of the Southern Urals: Protected Areas of the Chelyabinsk Region, Methodological Developments of Different Levels. Her research interests are Animal Biology, Environmental Biomonitoring, and Modern Problems of Ecology and Nature Management.



**Makarova Tatyana Nikolaevna** is an Associate Professor of the Department of Biology, Ecology, Genetics and Animal Breeding, South Ural State Agrarian University. She graduated from the Veterinary Department of the Ural State Institute of Veterinary Medicine (UGVM). She is a Candidate of Biological Sciences Her main research is the biodiversity of plants and invertebrates in the Southern Urals, the biological aspects of game animals, and the physiological and electrocardiographic features of rabbits.



**Kanagina Irina Rudolfovna** is an Associate Professor of the Department of Biology, Ecology, Genetics and Animal Breeding, South Ural State Agrarian University. She is a Candidate of Agricultural Sciences. Her research interests are Animal Biology; Biodiversity of the Chelyabinsk Region; Ecology of Plants and Animals of the Chelyabinsk Region.



**Dr. Medvedeva Larisa Vyacheslavovna** is an Associate Professor and Dean of the Faculty of Veterinary Medicine of Altai State Agrarian University. She holds a Doctor of Veterinary Sciences. Her research encompasses Veterinary Surgery.

**Note:** The original version of this article has been reviewed, accepted, and presented at the International Scientific and Practical Conference "From Inertia to Development: Scientific and Innovative Support for Agriculture" (IDSISA2020) at the Ural State Agrarian University, Ural, Russia, during 19-20 February 2020.