

PATHOMORPHOLOGICAL FEATURES OF THE COURSE OF MYCOSES CAUSED BY FUNGI OF THE GENUS MUCOR, ASPERGILLUS, IN MAMMALS, BIRDS, AND REPTILES

L.I. Drozdova¹, N.I. Zhenikhova¹, O.V. Badova², E.I. Popkov¹, V.E. Shakirov^{1*}

¹ Department of Morphology and Expertise., Federal State Budgetary Educational Establishment of Higher Education Ural State Agrarian University, Ekaterinburg, RUSSIA.

² Department of Infectious and Non-communicable Pathology, FSBEI HE Ural State Agrarian University, Ekaterinburg, RUSSIA.

ARTICLE INFO

Received 06 January 2020
Received in revised form 02 March 2020
Accepted 06 April 2020
Available online 16 April 2020

Keywords:

Mycoses;
Pathomorphology;
Aspergillosis;
Candidiasis;
Mucormycosis; Reptiles;
Mammals; Birds.

ABSTRACT

The work is devoted to the study of the pathomorphology of mycotic diseases in mammals, birds, and reptiles. The work aims to study the morphology and characteristics of the pathomorphogenesis of mycoses in different animals, the pathological anatomical and histological figures of these diseases. The study analyzes changes in the body of various animal species under the influence of fungal infections caused by fungi of the genus *Aspergillus*, *Mucor*. Consideration of the pathomorphological manifestations of mycoses was carried out at the Department of Morphology and Expertise of the Ural State Autonomous Administration.

To describe the manifestation of fungal infections, we performed an autopsy, followed by histological examination of pathological material from two camels, one swan, three budgies, a Bengal tiger, seven goats, and 69 reptiles, with a preliminary diagnosis of mycosis, according to generally accepted methods. The study showed that mycotic diseases in reptiles are quite common in the practice of a veterinarian. Analyzing the occurrence of fungal diseases, it found that mycoses caused by fungi of the genus *Aspergillus* accounted for 52% of cases, *Candida* 26%, *Mucor* 16%, and mixed mycoses 6%. In the study of mycoses, we found pathological changes in such organs as the liver, lungs, spleen, kidneys, adipose tissue, in the stomachs, pancreas and intestines. These changes were mainly in the nature of a granulomatous process.

Disciplinary: Animal Sciences, Biological Science, Biotechnology.

©2020 INT TRANS J ENG MANAG SCI TECH.

1. INTRODUCTION

Reptiles, birds, and various species of exotic mammals in recent years have become increasingly popular as companion pets. [4, 15] Many owners, not having sufficient experience, cannot provide adequate conditions for keeping and feeding for their animals. [16] This, in turn, leads to a decrease in the natural resistance of the animal organism, and, as a consequence, to the development of infectious and parasitic diseases, primarily mycoses. [17,18.19]

Mycoses are fungal diseases of animals, which are characterized by active parasitization of a pathogenic fungus in a living organism. [2] Almost all species of animals are susceptible to fungal infections. [1] Some of them are dangerous for humans, especially for children. [1] The causative agents of mycosis are classified as lower and higher fungi, as well as actinomycetes. [3] They are widespread in nature. In the body of animals, they can cause a pathological process with localization mainly in the skin, hairline, respiratory organs, digestive tract, genitourinary organs, and even in the brain tissue [4]. Mycoses are observed all year round, but more often in the winter-autumn period. Mostly mycoses affect young animals. The development of the disease depends on the degree of pathogenicity of the pathogen, predisposing factors, the stability of the macroorganism and environmental conditions. Mycoses also occur as secondary diseases in case of damage to the respiratory system, against the background of digestive disorders caused by exposure to antibiotic drugs. [5,6] S. Petrovich (1989) conditionally divides all mycoses of animals into 2 large groups: superficial and deep, or visceral, characterized, as a rule, by damage to internal organs and tissues. [7]

Many mycoses are characterized by simultaneous damage to the outer integument and internal organs. [12] However, it should be noted that in some cases superficial mycoses (trichophytosis) can be accompanied by damage to internal organs and deep-lying tissues, and visceral mycoses (candidiasis or aspergillosis) - only damage to the skin. But such cases are atypical and cannot have a significant impact on the fundamental separation of all known mycoses into superficial and deep. [8]

In the group of visceral mycoses, it is advisable to distinguish mold mycoses, which usually develop against the background of a decrease in the overall resistance of the body. Mycoses of fish and bees are also considered independent groups. [9] Under suitable conditions, a pathogenic fungus in the form of spores or mycelium is introduced and multiplies in the tissues, giving rise to a mycotic process. [11,13]

Diagnosis of these diseases is complicated by the absence of characteristic clinical predictors, the need for a detailed mycological study, and the wide species diversity of pathogen fungi. [20]

2. RESEARCH RESULTS

When analyzing the studied results, it found that visceral mycoses *Aspergillus*, *Mucor* are found in all animal species and quite often. During the research period, the structure of the ratios of individual visceral mycoses *Aspergillus*, *Candida*, *Mucor*, which were found in our work in various species and age groups of animals, was established. So, *Aspergillus* accounted for 52% of cases, *Candida* - 26%, *Mucor* - 16%, and mixed mycoses - 6%. The data is presented in Diagram 1.

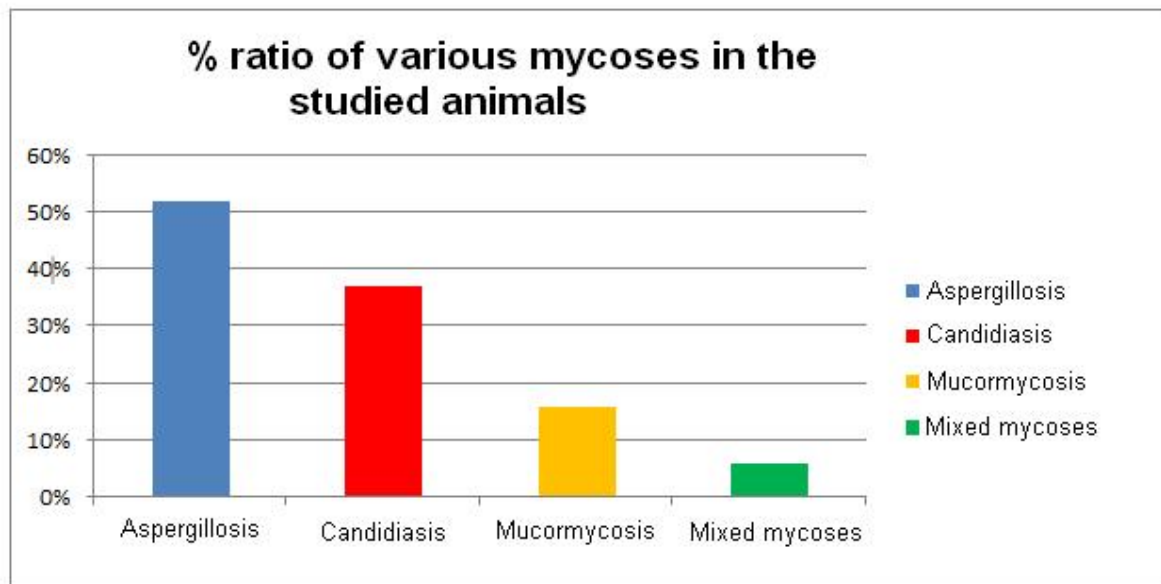


Diagram 1: The percentage of occurrence of various types of mycoses in the studied animals.

3. PATHOMORPHOLOGY OF ASPERGILLOSIS IN MAMMALS, BIRDS, AND REPTILES

Aspergillosis was recorded in 43 of the 83 studied animals, which indicates a 52% incidence of this disease. Aspergillosis was accompanied by a different nature of lesions of the respiratory system, the gastrointestinal tract, parenchymal organs, and central nervous system organs. Aspergillosis in birds was detected in 3 parrots and 1 swan. Changes in organs during the autopsy were characteristic of aspergillosis. Often attracted attention to single or multiple brownish foci, clearly revealed on the serous membrane of the muscle and glandular stomach and intestines. Around such foci, it was possible to see point hemorrhages, and palpation of these areas indicated a thickening of the wall of the affected organ. In such cases, ulcers could always be seen on the mucous membrane. In the liver, compacted nodular growths up to the size of a pea were found, which protruded above the surface of the organ due to which it was tuberous. The liver was always in a state of dystrophy up to the presence of clearly delimited necrosis. The nodules had a brownish tint, and on their surface there were greenish films densely fused with the nodules. In other cases, multiple superficial or deep necrosis was detected. Almost regular and of the same type were lesions of the valvular apparatus of the heart in the form of small or rather large hematomas up to a millet grain, or spotty hemorrhages, which were localized at the base of the valves. In the brain, the vessels are heavily injected, the dura mater is reddened, and hemorrhages in the white and gray matter.

Most often, aspergillosis lesions were observed in parrots and a swan in the lungs. The lung tissue is edematous diffuse red with the presence of grayish lesions and areas of hepatization. In chronic cases, single or multiple white-yellow nodules of caseous consistency of different sizes were found, necrosis and caverns resembling tuberculous lesions were noted. The mucous trachea was often covered with grayish-green films, serous-fibrinous inflammation of the bronchi was noted, which were filled with fibrinous contents with fungal hyphae. A mulunomatous process was observed in the lungs, in parenchymal organs, and on the serous membranes. A gray-white plaque was found on the pericardium. The airbags were also struck. Catarrh was detected in the digestive tract.

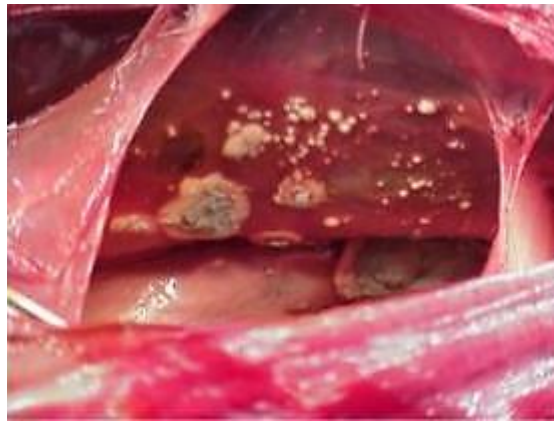

Figure 1: Air bags, light. Swan growth *Aspergillus fumigatus*

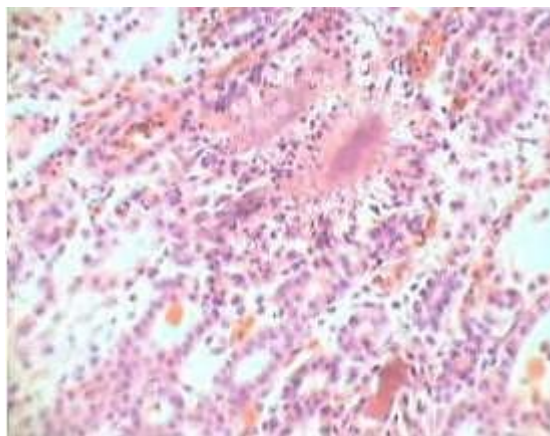


Figure 2: The kidney. Swan. *Aspergillus* granuloma. UV.3X60. Hematoxylin and eosin stain.

In a tiger, aspergillosis also occurred with lung damage in the form of granulomatous nodules, foci of tissue compaction, foci of necrosis, emphysema, and damage to the digestive tract and liver.

In goats, in addition to lung lesions, the presence of granular or fatty degeneration of the liver was observed. We have identified hemorrhagic heart attacks of a dark red color in the gastrointestinal tract. Hemorrhages were detected in the spleen and kidneys, the spleen was enlarged. During the histological examination of organs from 7 dead Nubian goats, fungal hyphae that were detected in vessels were constantly found in the wall of the abomasum, intestines, and leaflets of the book. Mycotic thrombi caused hemorrhagic heart attacks in the lungs. Lymphadenitis was especially common in the regional lymph nodes of the lungs and the gastrointestinal tract, and in the spleen, there was a weak leukocyte infiltration with a decrease in the number of follicles. A fairly common feature in other organs was vacuole dystrophy. In the intestinal mucosa, desquamations of the epithelium, edema, and hyperemia were detected. A feature of the defeat of the mucous membrane of the gastrointestinal tract in goats during aspergillosis was vacuolization of epithelial cells, which was not found with other mycoses.

When opening reptiles, the mucous membranes of the nasal and oral cavities were cyanotic, multiple point and banded hemorrhages were revealed under the epicardium. The surface of the lungs was dotted with solid nodules of the gray-yellow color of different sizes. The lungs were compacted, the tissue was pierced by small dense nodules at the incision, and a cloudy liquid containing fungal hyphae flowed out. Figures 1 and 2 correspond to the stage of red hepatization. About 80% of lung

tissue was occupied by granulomas. The macroscopic of the affected stomach with mold mycosis caused by aspergillus was characterized by the presence of yellow-brown ulcers and surrounded by a belt of hyperemic and hemorrhagic mucous membrane dotted with hemorrhages. At the bottom of the ulcers, a layer of necrotic tissue was usually observed, in which there were branching and interwoven threads with spherical thickenings at the ends. Tissue necrosis was the result of the toxic effects of the fungus and venous thrombosis with fungal hyphae.

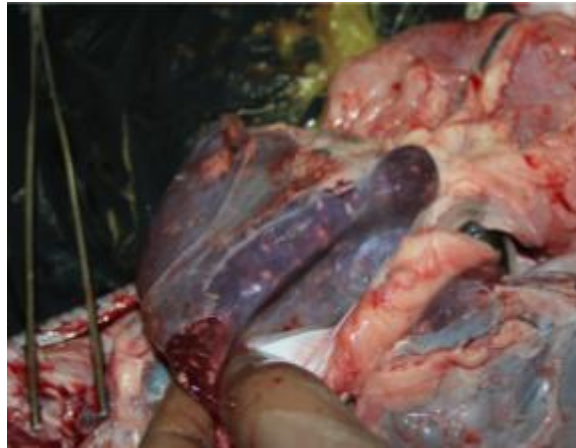

Figure 3: Multiple granulomatous processes in the liver of the Nile crocodile in aspergillosis.

In all the studied animals, a histological examination of the affected areas of the lungs revealed a large number of granulomas with colorless hyphae of the fungus, as well as a weak inflammatory reaction with a predominance of proliferation. The fungus was found mainly in unaffected tissue, but in areas of necrosis, it quickly decayed. Mycelium of the fungus, growing radially, formed strongly branching hyphae that invaded the lumen of blood vessels, alveoli, bronchioles. The walls of many bronchioles and blood vessels turned out to be germinated mycelium, which vegetates, penetrating into the underlying tissue in the direction and place in which we see the branching of its terminal parts. In the aspergillus nodules, 3 zones were revealed: the central one with necrotic decay, then the site with serous-fibrinous inflammation and mycelium of the fungus — a wide zone of granulation tissue.

The peculiarity of the growth of the fungus in the blood vessels is revealed. Having penetrated the adventitial layer, the mycelium grew perpendicular to the vessel wall to the ring muscles, and then along the muscle fibers around the vessel moved towards the lumen. In this case, an accumulation of lymphoid cells, white blood cells, and macrophages was noted around the vessels. Aspergillus was found in tissues in mycelial and drusen-like forms, and phagocytosis was carried out due to macrophages and giant cells. In the spleen, rarefaction of the cellular elements of the white pulp follicles was noted. The follicles were not clearly contoured, but their centers and the pulp cords of the white pulp were clearly colored. In several cases, loosening, edema, and exfoliation of the pia mater from the underlying brain substance were found in the brain. Congestive hyperemia and edema of the brain and meninges, as well as perivascular edema were noted.

Seeding from the affected tissue sites gave rise to *Aspergillus fumigatus*, which confirmed the results of studies on aspergillosis.

4. PATHOMORPHOLOGY OF MUCORMYCOSIS IN MAMMALS, BIRDS AND REPTILES.

Mucorosis was recorded in 13 of 83 studied animals, which indicates 16% of the incidence of this disease.

The main pathological changes in mucorosis were found in the digestive tract or respiratory system, as well as in adipose tissue.

A feature of mucoroses, unlike other deep mycoses, was a rarely observed inflammatory reaction in the affected tissues. If inflammation did occur, it was manifested by weak leukocyte and lymphocytic infiltration with necrotic changes. Abscessing was rare and almost no foci of purulent inflammation were detected. Often found tissue necrosis, which is characteristic of mucous lesions, it is associated with circulatory disorders. Mucous fungi grew into the walls of blood vessels and formed thrombi from the plexus of threads in their lumen, which led to impaired blood circulation, the formation of necrosis and heart attacks. Often, mushroom fungi were found in blood vessels.

Mucormycosis proceeded as acute systemic mycosis. At the opening of 2 camels and 11 reptiles, it was noted that the animals were cachexic and dehydrated, the camel's hair was dull, the hair was poorly held in the hair follicle. We have identified granulomas in all organs (heart, liver, spleen, brain, lungs). Fungal hyphae were detected histologically, as a rule, in vessels and foci of heart attacks, as well as in adipose tissue. The main accumulation of fungi was observed in the lesions of the lungs.

Describing the nature of pathomorphological changes in mucoroses in the studied animals, pathognomonic Figure 3 was revealed that did not raise doubts about the effect of this particular pathogen. These changes were characterized by bloody contamination of the area of the cloaca of reptiles and anus in camels, as well as swelling of the larynx. At the opening of the camels, a red-yellow, turbid fluid flowed from the abdominal cavity, and the serous membranes were covered with fibrin threads and multiple petechial hemorrhages were noted. The wall of the pancreas, at the same time, was saturated with blood, there were ulcers in the pyloric part. The mucous membrane of the pancreas was blue-violet, torn when touched. Blood clots and ulcerations of the mucous membrane were found in the small intestine. Lymph nodes were enlarged, swollen, with hemorrhages. In the liver, in almost all the studied animals, small necrotic foci were detected.

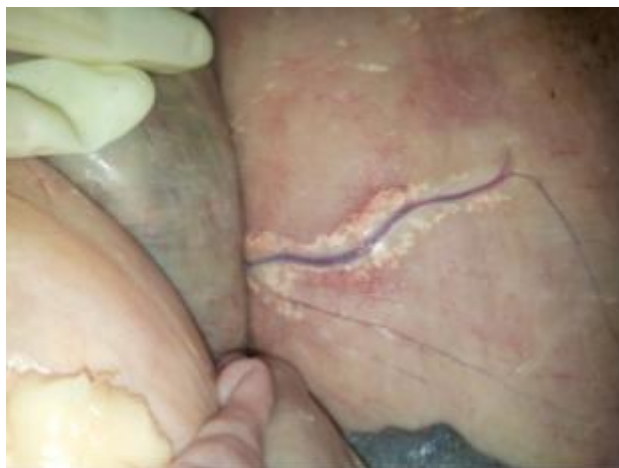

Figure 4: Camel, fibrinous overlay on the serous membrane and along the blood vessel. Multiple petechial hemorrhages.

Changes in the form of necrosis and hemorrhagic inflammation were localized in the intestines, abomasum, liver, lymph nodes, lungs. The fungus was also found in blood vessels and beyond. *Mucor* mushroom hyphae were present only in ulcers or foci of necrosis and were not found in healthy organs. Under the pericardium and on the endocardium of reptiles, there were spot hemorrhages.

The contents of the abomasum of camels were dark brown with an admixture of darkened straw, the mucous membrane was covered with grayish-white mucus, and sections of anemia and redness alternated. In addition, multiple, sharply delimited, or merging with each other ulcers of a rounded shape with raised edges of various diameters were detected on the mucous membrane. These ulcers protruded significantly above the surface of the mucous membrane and were covered with a gray-white coating, especially in the center.

All parts of the intestines of reptiles were in a state of catarrhal-hemorrhagic inflammation, both from the serous and mucous membranes. The intestinal contents were absent. Attention was drawn to the structural features of heart attacks, which in python and iguanas had a ring-shaped shape and clearly differed even from the side of the serous membrane of the stomach.

In a pathomorphological study, changes were noted in the kidneys, which in all cases contained large abscesses, as a result of which the organ itself on the capsule side had a tuberous surface. In addition, necrosis occurred in the liver and spleen.

Histologically, the fungus was detected in the entire thickness of the wall of the stomach and in the blood vessels. Extensive foci of heart attacks and necrosis, proceeding according to the type of karyorexis with the decay of cell nuclei, were revealed. The fungus was rare in these areas and was almost completely destroyed. Its greatest accumulation was noted at the border of the affected and healthy tissue, as well as in adipose tissue. The morphology of the fungus in the tissues was noteworthy. In the thickness of the mucous membrane of the gastrointestinal tract, the fungus vegetated strongly, which indicated its active reproduction; it was detected in the form of fragments of threads with swelling at the tips of hyphae and along their length. During the histological examination of the kidneys, we revealed pronounced granular dystrophy of the epithelium of the convoluted tubules and multiple infiltrates from lymphoid cells located between the tubules or penetrating the entire kidney tissue, especially along the nephrons. Many glomeruli and convoluted tubules were necrotic and contained a wide, non-septated mycelium of the fungus. In most areas of the kidney tissue, hemorrhages and edema of their own capsule were noted. In the liver, interlobular connective tissue grows, along the veins we found pronounced lymphoid-leukocyte infiltrates. Extensive changes took place in the spleen: the red pulp was heavily infiltrated by lymphoid cells, the edematous follicles, with hemorrhages, foci of necrosis, in which a significant amount of broad filament of the fungus was also found.

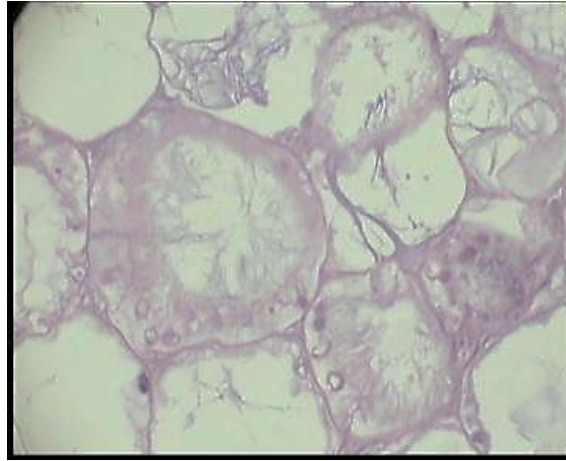


Figure 5: Adipose tissue of a camel. Mucoric growths in the lumen of the fat cell. Uv. 360X. Hematoxylin and eosin stain.

The lung tissue was hyperemic, edematous, many alveoli were filled with serous exudate, often revealed

The interalveolar septa and peribronchial connective tissue are infiltrated by lymphoid cells and white blood cells, bronchial lumens contained exudate.

Focal leukocyte infiltrates containing a large amount of mycelium of the fungus, swelling of the nuclei of myofibrils, perivascular edema, and hemorrhages in the myocardium were often noted in the thickness of the heart muscle. In skeletal muscle, the disappearance of transverse striation and granular dystrophy were observed.

Histologically, the *Mucor* fungus forms a wide, non-septated mycelium in the tissues, along which there are many short outgrowths.

Mycologically, a fungal culture of *Mucor pusillus* was isolated from the studied reptiles. A pathological fungus from the genus *Mucor* was isolated from camelids by a mycological study from foci of necrosis, as well as from fodder masses of the rumen and from fed hay.

5. CONCLUSION

Mycoses deserve special attention because the localization sites of mycotic lesions can be very different, it can be difficult to detect and diagnose them, so the intravital diagnosis of mycoses is rather difficult based on this, often

the outcome of mycoses is fatal, which indicates the relevance of this issue. Conducting our study, we came to the conclusion that pathomorphological changes in mycoses caused by a certain type of fungus are similar in different animal species. For example, in aspergillosis in birds, mammals and reptiles, the main changes will be detected in the lungs and will have a granulomatous process with a mild inflammatory response. Visceral mycoses should be considered as one of the fundamental causes of the death of animals, therefore, timely attention to the diagnosis of these diseases should be given special attention.

1. Pathomorphologically, aspergillosis, mucorosis and mixed mycoses are manifested by structural and functional lesions, primarily of the respiratory, digestive, immune and nervous systems.

2. In the differential pathomorphological diagnosis of visceral mycoses of animals it is established:

- in patients with aspergillosis, ulcers are observed in the gastrointestinal tract with ridged raised edges and a pinkish rim, necrosis is noted against the background of circulatory disorders. Granulomas of white-gray color, of various sizes are found in the lungs, and in the bronchi there is a fibrinous-hemorrhagic exudate with fungal mycelium, the fungal mycelium is septate, has a spherical appearance; contains a large number of pseudomycelia;
- with mucorosis, ulcers in the gastrointestinal tract, hemorrhagic heart attacks in the wall of the digestive tube, and sometimes fibrinous-hemorrhagic inflammation are observed. Foci of heart attacks are noticeable from the side of the serous membrane of the intestine, having the shape of a ring, hyphae of the fungus branching unpetuated;
- with mixed mycoses, changes in the organs combine the signs characteristic of the fungi that caused the disease.

6. REFERENCES

- [1] Agoltsov V.A. Localization of lesions and tissue reaction in experimental mycoses. Tomsk, 2015, 195, 15-18.
- [2] Vasiliev D.I. 2016. Veterinary herpetology. Aquarium-Print, Moscow, 420p.
- [3] Gosmanov, R.G. Workshop on Veterinary Microbiology and Mycology. The electron Dan SPb. 2015, 384p. <http://e.lanbook.com/book/45680>
- [4] Drobyshevsky S.V., Sidorova K.A. 2017. Mycotoxins as a source of animal poisoning. Young Scientist. 2(S), 249-251. <http://moluch.ru/archive/136/37319>.
- [5] Domnitsky I.Yu. Pathomorphological diagnosis of visceral mycoses. Doctor of Vet. Sciences Dissertation. Saratov, 2009. 43s
- [6] Zharov A.V., Adamushkina L.N., Loseva T.V., Strelnikov A.P. 2019. Pathological physiology and pathological anatomy of animals. Lan Publishing. 5th Ed., Sr. 2019 416 Art.
- [7] Zhenikhova N.I., Drozdova L.I. 2018. Pathomorphology of polymycoses in small cattle. Actual Problems of Veterinary Medicine: International Scientific-practical Conference dedicated to the 90th birthday of Professor V.A. Kirshin. Publisher: Federal Center for Toxicological, Radiation and Biological Safety. Kazan.
- [8] Kuznetsov A.F. 2016. Veterinary Mycology. Moscow, Ser. 11 Universities of Russia. 2nd Ed.
- [9] Popkov EI, Nikitin AP, Zhenikhova NI. 2015. Aspergillosis of waterfowl. IX International Scientific and Practical Conference "Modern Concepts of Scientific Research." December 27-30, Ch.8.. 133-136.
- [10] Sakhno N.V., Timokhin O.V., Vatnikov Yu.A., Kulikov E.V., Strizhakov A.A., Gnezdilova L.A. 2017. "On the technique of inoculation of infected and pathological material to laboratory animals". Vestnik KrasGAU. 7.
- [11] Tarasov K.L., Alexandrova E.N. 2015. Mycelial fungi - pathogens of crayfish mycoses and their modern toxemia. Mycology and phytopathology. 49(6), 366-373.
- [12] Ivanov NP, Sattarova R. 2015. Ethiological structure of the curators of mykosis agricultural animals in kazakhstan methods of fight against them. In the collection: I Eurasian Scientific and Practical Conference "Innovative Agrobiotechnology in Animal Husbandry and Veterinary Medicine" Executive Editor I.Ya. Us. S. 45-48.
- [13] Chkhenkeli V.A. 2014. Veterinary Mycology (Educational Aid). International Journal of Experimental Education. 11, 104-105.
- [14] Elad, D. 2018. Therapy of Non-Dermatophytic Mycoses in Animals. J Fungi (Basel). 4(4): 120.

- [15] Daniel Elad1 and Esther Segal Front. 2018. Diagnostic Aspects of Veterinary and Human Aspergillosis, Microbiol. DOI: 10.3389/fmicb.2018.01303
- [16] Paré, J.A., Sigler, L. 2016. An Overview of Reptile Fungal Pathogens in the Genera Nannizziopsis, Paranannizziopsis, and Ophidiomyces. Journal of Herpetological Medicine and Surgery 26(1-2), 46-53.
- [17] Kimberly L Rainwater, et al. 2019. Novel Paranannizziopsis species in a Wagler's viper (*Tropidolaemus wagleri*), tentacled snakes (*Erpeton tentaculatum*), and a rhinoceros snake (*Rhynchophis boulengeri*) in a zoological collection. Medical Mycology 825-832.
- [18] Huckabone, S.E., et al. 2015. Coccidioidomycosis and other systemic mycoses of marine mammals stranding along the central California, USA coast: 1998–2012. Journal of Wildlife Diseases: 2015, 51(2), 295-308.
- [19] Seyedmousavi, S., et al., 2018. An Martel, Bernard Mignon...Show more Fungal infections in animals: a patchwork of different situations. *Medical Mycology*, 56, S165–187.
- [20] Haerin Rhim and Jae-Ik Han. (2019) Nannizziopsis chlamydospora associated necrotizing dermatomycosis in a bearded dragon (*pogona vitticeps*). Journal of Exotic Pet Medicine.



Professor Dr. Drozdova Lyudmila Ivanovna is Professor and Head of the Department of Morphology and Expertise. She holds a Doctor of Veterinary Sciences. Her research interests include the study of the Morphology of Histo-hematological Barriers and their Permeability for various Pathogens in the Mother-Placenta-Fetus system in various Technogenic Zones



Dr. Zhenikhova Natalya Ivanovna is an Associate Professor of the Department of Morphology and Expertise. Candidate of Veterinary Sciences. Her research interests are Oncology, morphology, histology, pathomorphology, pathological anatomy, mammals, birds, reptiles



Dr. Badova Olga Viktorovna is an Associate Professor of the Department of Infectious and Non-communicable Pathology. She is a Candidate of Veterinary Sciences. Her research interests are Non-communicable Internal Diseases, Therapy, Histology, Morphology.



Popkov Egor Ivanovich is a Teacher of the Department of Morphology and Expertise. His research interests: Pathomorphology, Therapy of Small and Exotic Animals, Herpetology.



Shakirov Vyacheslav Evgenievich is a Graduate Student and a Teacher of the Department of Morphology and Expertise. His research interests are Pathological Anatomy, Pathomorphology, Histology, Forensic Veterinary Examination.

Note: The original version of this article has been reviewed, accepted, and presented at the International Scientific and Practical Conference “From Inertia to Development: Scientific and Innovative Support for Agriculture” (IDSISA2020) at the Ural State Agrarian University, Ural, Russia, during 19-20 February 2020.