



## Pathogenetic Features and Spread of Non-Pigmented (Amelanotic) Melanoma of the Skin

Tagir Magometovich Nalgiev<sup>1</sup>, Fatima Khamzatovna Dagaeva<sup>2</sup>, Zarina Olegovna Khubetsova<sup>3</sup>, Abdulla Saydalievich Majidov<sup>4</sup>, Busana Mansurovna Dadasheva<sup>4</sup>, Madina Tamerlanovna Kadieva<sup>5</sup>, Igor Alexandrovich Kostylev<sup>6</sup>, Madina Yusupovna Latyrova<sup>1</sup>, Abdusaid Abdumutalibovich Kurbanov<sup>5</sup>, Silviya Grayrovna Arzumanyan<sup>7</sup>

<sup>1</sup> Ingush State University, Magas, Republic Of Ingushetia, RUSSIA.

<sup>2</sup> North Ossetian State Medical Academy, Vladikavkaz, Republic of North Ossetia-Alania, RUSSIA.

<sup>3</sup> North Ossetian State University named after Kosta Levanovich Khetagurov, Vladikavkaz, Republic of North Ossetia-Alania, RUSSIA.

<sup>4</sup> Chechen State University named after A.A. Kadyrov, Grozny, Republic of Chechnya, RUSSIA.

<sup>5</sup> Dagestan State Medical University, Makhachkala, Republic of Dagestan, RUSSIA.

<sup>6</sup> St. Petersburg State Medical Academy named after I. I. Mechnikov, St. Petersburg, RUSSIA.

<sup>7</sup> Rostov State Medical University, Rostov-on-Don, RUSSIA.

\*Corresponding Author (Tel: +79183500889, Email: [ruslankalmykov777@yandex.ru](mailto:ruslankalmykov777@yandex.ru)).

Paper ID: 13A11E

Volume 13 Issue 11

Received 23 April 2022

Received in revised form 01

July 2022

Accepted 08 July 2022

Available online 15 July

2022

### Keywords:

Amelanotic melanoma;

Dermatoscopy;

Melanoma;

Pathogenesis;

Epidemiology;

Epiluminescent

microscopy; Melanocytic

skin lesion; Non-

melanocytic skin lesion.

### Abstract

Amelanotic malignant melanoma (non-pigmented melanoma) is a subtype of skin melanoma with little or no pigment on visual examination and is one of the most difficult-to-diagnose clinical conditions. It can mimic benign and malignant variants of both melanocytic and non-melanocytic lesions. Amelanotic melanoma (AM) accounts for 1.8-8.1% of all melanomas. The exact incidence is difficult to calculate since the term pigmented melanoma is often used to clinically describe any melanoma that is only partially devoid of pigment. True non-pigmented melanoma is rare, i.e. it does not produce any discernible eumelanin (so-called pure AM), there are also melanomas producing low levels of eumelanin (i.e. hypomelanous melanomas). Such melanomas may seem pigmented. From a clinical point of view, the diagnosis of non-pigmented melanoma is a difficult task for the reason that the clinical and diagnostic signs that are usually associated with melanomas (asymmetry, uneven borders and variegation of color) are rarely present in AM. Thus, in about 50% of cases, the differential diagnosis varies from inflammatory to benign neoplastic formations, which leads to late diagnosis.

**Discipline:** Medicine, Dermatology.

©2022 INT TRANS J ENG MANAG SCI TECH.

### Cite This Article:

Nalgiev, T.M., Dagaeva, F.Kh., Khubetsova, Z.O., Majidov, A.S., Dadasheva, B.M., Kadieva, M. T., ... Arzumanyan, S.G. (2022). Pathogenetic features and spread of non-pigmented (amelanotic) melanoma of the skin. *International Transaction Journal of Engineering, Management, & Applied Sciences & Technologies*, 13(11), 13A11E, 1-9. <http://TUENGR.COM/V13/13A11E.pdf> DOI: 10.14456/ITJEMAST.2022.215

# 1 Introduction

Only 0.4–27.5% of all melanoma cases are classified as amelanotic melanoma. It is reported that the frequency of true pigmented melanoma from the total number of melanomas is less than 2% [1]. Non-pigmented melanoma (Amelanotic melanoma) is difficult to diagnose and contributes to increased mortality from melanoma, since AM is usually diagnosed at later stages, with a lower overall survival rate than pigmented melanomas (PM) [1-3]. Despite epidemiological studies conducted over the past few decades that have identified some common risk factors for the development of melanoma, specific risk factors of AM have not been sufficiently studied [4,5]. Non-pigmented melanomas are more often detected in women, which are characterized by: thicker contours, lack of coexisting nevus, nodularity, as well as with a large number of mitoses and heavy adjacent solar elastoses. It was also found that non-pigmented melanomas are associated with the absence of nevi on the back, which are reported by patients themselves, and a skin type more sensitive to the sun than in patients with pigmented melanomas [6]. In patients with non-pigmented melanoma, the disease is diagnosed at an older age than in patients with pigmented melanoma (average age 59 years versus 51 years ( $P < 0.001$ )) [7]. Amelanotic malignant melanoma, as a rule, occurs on the skin exposed to sunlight, especially in elderly people with photodamage, and can manifest as erythematous, sometimes scaly, spots or plaques with uneven edges, imitating benign inflammatory plaques, superficial basal cell carcinoma (BCR), actinic keratosis, Paget's disease or Bowen.[8] It can also manifest as translucent papules, thereby resembling basal cell carcinoma, or it may clinically resemble keratoacanthoma or carcinoma from Merkel cells.[9] Alternatively, it may manifest as an exophytic node, often eroded, mimicking pyogenic granuloma or hemangioma, or as a skin plaque/node known as desmoplastic malignant melanoma.[10] Amelanotic melanoma is usually diagnosed in patients older than 50 years – older than in patients with PM [11]. However, about 70% of melanomas in children are amelanotic [12]. The association of non-pigmented melanoma with gender is contradictory: various studies show that AM is more common in men [13,14], women [15], or lacks of gender [16]. The presumed predisposition of women may be due to the fact that women are more likely than men to report suspicious skin diseases, while the possible predominance of men may be associated with more frequent outdoor exposure. Amelatic melanoma is predominantly found in white patients and more often in persons with type I skin and red hair or with oculocutaneous albinism [17]. A population study also showed that freckles, the absence of nevi on the back, a phenotype sensitive to sunlight, and a previous history of AM increase the risk of developing non-pigmented melanoma [17]. It is important to understand that any of the four subtypes of melanoma (superficially spreading, nodular, acrolentiginous and malignant lentigo) can occur as an amelanotic variant [18].

As a rule, based on clinical and dermatoscopic data, amelanotic melanoma is divided into two subtypes: true AM and hypomelanous melanoma [19]. True non-pigmented melanomas (also called completely or completely pure amelanotic melanomas) do not have noticeable melanin formation and do not show pigmentation either during a visual examination or dermatoscopic

evaluation. Hypomelanotic melanoma or incomplete AM, with a low level of melanin formation, clinically does not show obvious pigmentation but show partial or weak pigmentation during dermatoscopic examination. In addition, since melanin is usually detected histopathologically in AM, some authors use a stricter criterion for determining true non-pigmented melanoma: completely amelanotic not only clinically, but also dermatoscopically, with melanin in less than 5% of tumor cells during histological examination [20,21].

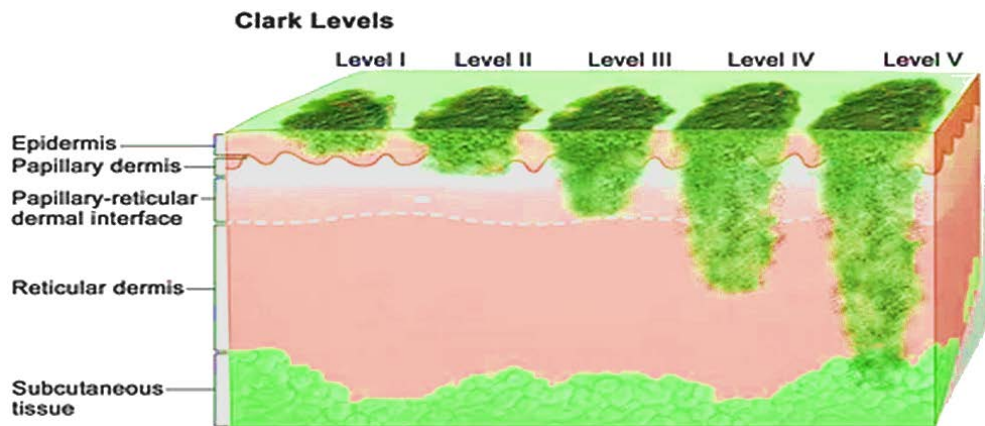
The mechanism underlying amelanosis is still unclear. In previous studies of non-pigmented melanoma, it was considered as a dedifferentiated or low-differentiated melanoma [22]. However, like its pigmented analogues, amelanotic melanoma cells retain their melanocytic origin and melanin-forming ability due to the expression of tyrosinase and transcription factor associated with microphthalmos (MITF) [23]. Moreover, Cheung et al. (2012) found few low-grade tumor cells in samples of non-pigmented melanoma [15]. Thus, amelanotic melanoma is rather a subtype of melanoma that retains the ability to form melanin, rather than a dedifferentiated or low-grade melanoma. In samples of non-pigmented melanoma, a decrease in the expression of specific melanin formation enzymes (such as tyrosinase) was observed, which indicates that amelanosis or hypomelanosis may be a consequence of insufficient activity or amount of tyrosinase [24,25].

Pouryazdanparast et al. (2009) believe that the phenotype of amelanotic melanoma, especially with an increase in the number of copies in the 8q24 chromosome, may be caused by suppression of tyrosinase and other melanocyte-specific genes mediated by the absence of MITF expression [26]. In addition to an increase in the number of copies in 8q24, germline mutations in the MC1R, MITF and p14ARF genes can also lead to pigmentation-free melanoma. Support for the role of somatic gene mutations (e.g. BRAF and KIT) in the development of amelanotic melanoma varied in different studies. Frequent frequency of BRAF and KIT mutations in amelanotic melanoma (70.3 and 12.1% in whites and 6.1 and 12.1% in Asians, respectively) and a higher frequency of KIT aberrations in fully amelanotic acral melanoma than in pigmented acral melanoma (12.1 vs. 7.3% [20]). However, other studies have shown that hyperpigmentation of melanoma is closely related to KIT changes [27] and BRAF mutations [28].

## 2 Clinical Features

Adler and White (1997) proposed three main clinical forms of non-pigmented melanoma: (a) erythematous spot with changes in the epidermis on the skin exposed to the sun, (b) flesh-colored dermal plaques without changes in the epidermis, and (c) papulonodular form [29]. The papulonodular form accounts for 58% of cases of amelanotic melanoma and can manifest itself as an ulcerated node or vascular lesion, as well as mimic pyogenic granuloma or hemangioma. Non-papulonodular forms of non-pigmented melanoma may look like erythematous spots or spots, or as scaly eczema-like or cutaneous skin plaques [30]; they rarely show "ABCD" criteria (asymmetry, uneven borders, variegation of color, diameter > 6 mm), which usually contribute to the diagnosis and screening of melanomas [31]. A subtle blush or peripheral rim of pigment is often observed around amelanotic lesions, but not around true AM [32]. Despite the absence of melanin,

pigmented melanomas can be flesh-colored, red, pink, or erythematous, among which red pigmented melanomas account for almost 70% [33]. Amelanotic melanoma occurs in all parts of the body, with a higher incidence of lesions on the face and extremities than pigmented melanoma. [34].



**Figure 1:** Stages of melanoma disease. (after [41]).

**Table 1:** Determination of the stage of skin melanoma by three criteria

Stage	Tumor thickness	Metastases to regional lymph nodes	Metastases to internal organs
0	within the epidermis	no	no
I A	to the papillary layer of the dermis, the mesh (deep) does not affect, there are no ulcers	no	no
I B	penetrates into the deep layer of the dermis, possibly into the subcutaneous tissue (thickness — from 1 to 2 mm), no ulcers	no	no
II A	the thickness of the tumor is from 1 to 2 mm, there is ulceration or thickness from 2 to 4 mm, no ulcers	no	no
II B	thickness from 2 to 4 mm, with ulceration or thickness above 4 mm, without ulcers	no	no
II C	thickness greater than 4 mm, with ulceration	no	no
III A	any thickness, ulcers not yet	there are micrometastases in 1-3 regional lymph nodes	no
III B	any thickness, without ulceration	or macrometastases in 1-3 regional lymph nodes or metastases to the skin near the tumor, but without metastases in regional lymph nodes	no
	any thickness, with the formation of ulcers	or micrometastases in 1-3 regional lymph nodes or metastases to the skin near the tumor, but without metastases in regional lymph nodes	no
III C	any thicany thickness, with ulceration	or micro- or macrometastases in 2-3 regional lymph nodes	no
	any thickness	more than 3 regional lymph nodes are affected by metastases, or there are several affected lymph nodes soldered together, or there are metastases in the skin near the tumor, despite the fact that they also exist in regional lymph nodes	no
IV	any size	any quantity	yes

In its development, non-pigmented melanoma can go through 4 stages (Figure 1). Each of them, except for the fourth, is divided into several sub-stages.

The stages are determined according to three criteria:

1. the thickness of the tumor (the depth of its germination into the skin);
2. metastases to regional lymph nodes;
3. metastases to internal organs.

The distribution of non-pigmented melanoma varies among different races. Among Asian patients in whom the most frequent subtype of melanoma is acral melanoma, amelanotic melanoma often occurs in acral areas with the highest frequency of 20-28% [35]. On the contrary, non-pigmented melanoma in white patients is more common in areas damaged by the sun due to the predominance of non-oral melanoma [36]. It is reported that the location of AM also varies depending on gender, with the trunk prevailing in men and the limbs in women [37].

### 3 Forecast

Patients with non-pigmented melanoma, as a rule, have an unfavorable prognosis. Although some studies have not found a significant difference in survival between patients with amelanotic melanoma and pigmented melanoma, other studies with larger case series show that patients with AM often have a significantly higher risk of death and relapse, as well as lower melanoma-specific survival [38].

In addition, in a large 2012 study of patients with primary melanoma of the skin, it was also reported that melanosis does not have a prognostic effect after taking into account risk factors, including tumor stage, Breslow thickness, invasion rate, mitosis rate and ulceration [39]. A population-based GEM study showed that amelanosis does not have a prognostic effect on survival if the tumor stage is taken into account, according to the American Joint Committee on Cancer, which indicates that the worse prognosis for non-pigmented melanoma compared to pigmented melanoma was completely caused by a later stage of the tumor when diagnosed [40]. Thus, the unfavorable prognosis of AM may be mainly due to the late stage of the tumor, negative prognostic factors (such as deep tumor thickness and high mitosis rate) or potentially greater aggressiveness.

### 4 Conclusion

Amelanotic melanoma is a special form of melanoma that differs from pigmented melanoma in many ways. Non-pigmented melanomas can mimic many benign or malignant conditions in the absence of pigmentation, and due to possible erroneous or delayed diagnosis and possible aggressiveness of amelanotic melanomas. They are often diagnosed at late stages with a poor prognosis. Clinicians should be aware of every potential manifestation of non-pigmented melanoma and take melanoma into account in the differential diagnosis of suspicious lesions. The use of advanced techniques (such as dermatoscopy) can also help in the earlier diagnosis of AM. Further research is needed to uncover the underlying mechanism of melanosis in these tumors, and to describe their characteristic biological behavior.

## 5 Availability of Data and Material

Data can be made available by contacting the corresponding authors.

## 6 References


- [1] Moreau JF, Weissfeld JL, Ferris LK. Characteristics and survival of patients with invasive amelanotic melanoma in the USA. *Melanoma Res.* 2013;23(5):408-13. DOI: 10.1097/CMR.0b013e32836410fe
- [2] Thomas NE, Kricger A, Waxweiler WT, Dillon PM, Busman KJ, From L, Groben PA, Armstrong BK, Anton-Culver H, Gruber SB, Marrett LD, Comparison of clinicopathologic features and survival of histopathologically amelanotic and pigmented melanomas: a population-based study. *JAMA Dermatol.* 2014;150(12):1306-14. DOI: 10.1001/jamadermatol.2014.1348
- [3] Gandini S, Sera F, Cattaruzza MS, Pasquini P, Zanetti R, Masini C, Boyle P, Melchi CF. Meta-analysis of risk factors for cutaneous melanoma: III. Family history, actinic damage and phenotypic factors. *Eur J Cancer.* 2005;41(14):2040-59. DOI: 10.1016/j.ejca.2005.03.034
- [4] Hogue L, Harvey VM. Basal Cell Carcinoma, Squamous Cell Carcinoma, and Cutaneous Melanoma in Skin of Color Patients. *Dermatol Clin.* 2019;37(4):519-26. DOI: 10.1016/j.det.2019.05.009
- [5] Strazzulla LC, Li X, Zhu K, Okhovat JP, Lee SJ, Kim CC. Clinicopathologic, misdiagnosis, and survival differences between clinically amelanotic melanomas and pigmented melanomas. *J Am Acad Dermatol.* 2019;80(5):1292-1298. DOI: 10.1016/j.jaad.2019.01.012
- [6] Goldsmith SM. Comment on "Clinicopathologic, misdiagnosis, and survival differences between clinically amelanotic melanomas and pigmented melanomas". *J Am Acad Dermatol.* 2021;85(6):e361. DOI: 10.1016/j.jaad.2019.01.089
- [7] Chamberlain AJ, Fritschi L, Kelly JW. Nodular melanoma: patients' perceptions of presenting features and implications for earlier detection. *J Am Acad Dermatol.* 2003;48(5):694-701. DOI: 10.1067/mjd.2003.216
- [8] Mensing C, Livingstone E, Schwarz T, Hauschild A. Eczematous malignant melanoma: a wolf in sheep's clothing. *Onkologie.* 2009;32(4):206-8. DOI: 10.1159/000203334
- [9] Cahill S, Cryer JR, Otter SJ, Ramesar K. An amelanotic malignant melanoma masquerading as hypergranulation tissue. *Foot Ankle Surg.* 2009;15(3):158-60. DOI: 10.1016/j.fas.2008.11.006
- [10] Ahmed B, Qadir MI, Ghafoor S. Malignant Melanoma: Skin Cancer-Diagnosis, Prevention, and Treatment. *Crit Rev Eukaryot Gene Expr.* 2020;30(4):291-297. DOI: 10.1615/CritRevEukaryotGeneExpr
- [11] Merkel EA, Mohan LS, Shi K, Panah E, Zhang B, Gerami P. Paediatric melanoma: clinical update, genetic basis, and advances in diagnosis. *Lancet Child Adolesc Health.* 2019;3(9):646-654. DOI: 10.1016/S2352-4642(19)30116-6.
- [12] Boraeva, T. T., Vadaeva, M. A., Matveeva, U. V., Revazova, A. B., Albegova, B. Z., Kanukoeva, D. T., Mishvelov, A. E. and Povetkin, S. N. Dynamics of Diseases of the Upper Digestive Tract in Children, *Journal of Pharmaceutical Research International*, 2021; 33(38B), 48-57. DOI: 10.9734/jpri/2021/v33i38B32098
- [13] McDonald JS, Miller RL, Wagner W, Giammara B. Acral lentiginous melanoma of the oral cavity. *Head Neck Surg.* 1983;5(3):257-62. DOI: 10.1002/hed.2890050311
- [14] Gualandri L, Betti R, Crosti C. Clinical features of 36 cases of amelanotic melanomas and considerations about the relationship between histologic subtypes and diagnostic delay. *J Eur Acad Dermatol Venereol.* 2009;23(3):283-7. DOI: 10.1111/j.1468-3083.2008.03041.x
- [15] Cheung WL, Patel RR, Leonard A, Firoz B, Meehan SA. Amelanotic melanoma: a detailed morphologic analysis with clinicopathologic correlation of 75 cases. *J Cutan Pathol.* 2012;39(1):33-9. DOI: 10.1111/j.1600-0560.2011.01808.x
- [16] Detrixhe A, Libon F, Mansuy M, Nikkels-Tassoudji N, Rorive A, Arrese JE, Quatresooz P, Reginster MA, Nikkels AF. Melanoma masquerading as nonmelanocytic lesions. *Melanoma Res.* 2016;26(6):631-4. DOI: 10.1097/CMR.0000000000000294

- [17] Solano, Francisco. Melanins: Skin Pigments and Much More—Types, Structural Models, Biological Functions, and Formation Routes. *New Journal of Science*. 2014. 1-28. 10.1155/2014/498276
- [18] Ayivi R, Ibrahim S, Colleran H, Silva R, Williams L, Galanakis C, Fidan H, Tomovska J and Siddiqui SA. COVID-19: human immune response and the influence of food ingredients and active compounds. *Bioactive Compounds in Health and Disease*. 2021;4(6):100.
- [19] Hayward NK, Wilmott JS, Waddell N, Johansson PA, Field MA, Nones K, Patch AM, Kakavand H, Alexandrov LB, Burke H, Jakrot V. Whole-genome landscapes of major melanoma subtypes. *Nature*. 2017 ;545(7653):175-80. DOI: 10.1038/nature22071
- [20] Markiewicz A, Donizy P, Nowak M, Krzyziński M, Elas M, Płonka PM, Orłowska-Heitzmann J, Biecek P, Hoang MP, Romanowska-Dixon B. Amelanotic Uveal Melanomas Evaluated by Indirect Ophthalmoscopy Reveal Better Long-Term Prognosis Than Pigmented Primary Tumours—A Single Centre Experience. *Cancers*. 2022; 14(11):2753. DOI: 10.3390/cancers14112753
- [21] Thomas NE, Kricger A, Waxweiler WT, Dillon PM, Busam KJ, From L, Groben PA, Armstrong BK, Anton-Culver H, Gruber SB, Marrett LD. Comparison of clinicopathologic features and survival of histopathologically amelanotic and pigmented melanomas: a population-based study. *JAMA dermatology*. 2014;150(12):1306-14. DOI: 10.1001/jamadermatol.2014.1348
- [22] Cabrera R, Recule F. Unusual clinical presentations of malignant melanoma: a review of clinical and histologic features with special emphasis on dermatoscopic findings. *American Journal of Clinical Dermatology*. 2018;19(1):15-23. DOI: 10.1007/s40257-018-0373-6
- [23] Saliba E, Bhawan J. Aberrant Expression of Immunohistochemical Markers in Malignant Melanoma: A Review. *Dermatopathology*. 2021;8(3):359-70. DOI: 10.3390/dermatopathology8030040
- [24] Ranjha MMAN, Shafique B, Rehman A, Mehmood A, Ali A, Zahra SM, Roobab U, Singh A, Ibrahim SA and Siddiqui SA. Biocompatible Nanomaterials in Food Science, Technology, and Nutrient Drug Delivery: Recent Developments and Applications. *Front. Nutr*. 2022; 8:778155. DOI: 10.3389/fnut.2021.778155
- [25] Siddiqui SA, Bahmid NA, Taha A, Khalifa I, Khan S, Rostamabadi H, Jafari SM. Recent advances in food applications of phenolic-loaded micro/nanodelivery systems. *Critical Reviews in Food Science and Nutrition*. 2022:1-21. DOI: 10.1080/10408398.2022.2056870
- [26] Pouryazdanparast, P., Newman, M., Mafee, M., Guitart, J. & Gerami, P. Malignant melanoma with monster cells showing massive cyclin D1 amplification. *Am. J. Dermatopathol*. 2009; 31:402-3.
- [27] Goel, V., Ibrahim, N., Jiang, G. *et al*. Melanocytic nevus-like hyperplasia and melanoma in transgenic BRAFV600E mice. *Oncogene*. 2009;28:2289-98. DOI: 10.1038/onc.2009.95
- [28] Wu JM, Alvarez H, García P, Rojas PL, Wong G, Maitra A, Antonescu C, Montgomery EA. Melanoma hyperpigmentation is strongly associated with KIT alterations. *Am J Dermatopathol*. 2009;31(7):619-25. DOI: 10.1097/DAD.0b013e3181a23f3b
- [29] Adler, M.J., & White, C.R. Amelanotic malignant melanoma. *Seminars in cutaneous medicine and surgery*, 1997;16 2:122-30.
- [30] Reggiani C, Manfredini M, Mandel VD, Farnetani F, Ciardo S, Bassoli S, Casari A, Guida S, Argenziano G, Lallas A, Ulrich M, Pellacani G, Longo C. Update on non-invasive imaging techniques in early diagnosis of non-melanoma skin cancer. *G Ital Dermatol Venereol*. 2015;150(4):393-405.
- [31] Kalwa U, Legner C, Kong T, Pandey S. Skin Cancer Diagnostics with an All-Inclusive Smartphone Application. *Symmetry*. 2019;11(6):790. DOI: 10.3390/sym11060790
- [32] Liu, Y., Moore, A.T. Congenital focal abnormalities of the retina and retinal pigment epithelium. *Eye*. 2020;34:1973–88. DOI: 10.1038/s41433-020-0902-4
- [33] Sexton M, Sexton CW. Recurrent pigmented melanocytic nevus. A benign lesion, not to be mistaken for malignant melanoma. *Arch Pathol Lab Med*. 1991;115(2):122-6
- [34] Nuzhnaya KV, Mishvelov AE, Osadchiy SS, Tsoma MV, Rodin IA, Nagdalian AA. et al. Computer simulation and navigation in surgical operations. *Pharmacophore*. 2019;10(4):46-52.

- [35] Saeed DM, Braniecki M, Groth JV. A rare case of acral amelanotic melanoma, nodular type. *International Wound Journal*. 2019;16(6):1445-9. 10.1111/iwj.13212.
- [36] Farshidfar F, et al. Integrative molecular and clinical profiling of acral melanoma links focal amplification of 22q11. 21 to metastasis. *Nature communications*. 2022 23;13(1):1-6.. DOI: 10.1038/s41467-022-28566-4
- [37] Dobrică E-C, Vâjăitu C, Condrat CE, Crețoiu D, Popa I, Gaspar BS, Suciuc N, Crețoiu SM, Varlas VN. Vulvar and Vaginal Melanomas—The Darker Shades of Gynecological Cancers. *Biomedicines*. 2021; 9(7):758. DOI: 10.3390/biomedicines9070758
- [38] Mattia, G., Puglisi, R., Ascione, B. et al. Cell death-based treatments of melanoma:conventional treatments and new therapeutic strategies. *Cell Death Dis*. 2018;9,112. DOI: 10.1038/s41419-017-0059-7
- [39] Scolyer, R.A., Rawson, R.V., Gershenwald, J.E. et al. Melanoma pathology reporting and staging. *Mod Pathol*. 2020; 33,15-24 . DOI: 10.1038/s41379-019-0402-x
- [40] Phipps AI, Alwers E, Harrison T, Banbury B, Brenner H, Campbell PT, Chang-Claude J, Buchanan D, Chan AT, Farris AB, Figueiredo JC. Association between molecular subtypes of colorectal tumors and patient survival, based on pooled analysis of 7 international studies. *Gastroenterology*. 2020;158(8):2158-68. DOI: 10.1053/j.gastro.2020.02.029
- [41] Abdullah Z, Zaaba SK, Mustaffa MT, Mohamad CW, Mohtar JA. Review on Melanoma Skin Cancer Treatment by Cold Atmospheric Plasma. *Journal of Telecommunication, Electronic and Computer Engineering*. 2018;10(1-17):97-100.
- 



**Tagir Magometovich Nalgiev** is a Student of Ingush State University, Magas, Republic Of Ingushetia, Russia



**Fatima Khamzatovna Dagaeva** is a Student of the North Ossetian State Medical Academy, Vladikavkaz, Republic of North Ossetia-Alania, Russia



**Zarina Olegovna Khubetsova** is a Student of the North Ossetian State University named after Kosta Levanovich Khetagurov, Vladikavkaz, Republic of North Ossetia-Alania, Russia



**Abdulla Saydalievich Majidov** is a Student of the Chechen State University named after A.A. Kadyrov, Grozny, Republic of Chechnya, Russia



**Busana Mansurovna Dadasheva** is a Student of the Chechen State University named after A.A. Kadyrov, Grozny, Republic of Chechnya, Russia



**Madina Tamerlanovna Kadieva** is a Student of Dagestan State Medical University, Makhachkala, Republic of Dagestan, Russia





**Igor Alexandrovich Kostylev** is a Student of St. Petersburg State Medical Academy named after I. I. Mechnikov, St. Petersburg, Russia



**Madina Yusupovna Latyrova** is a Student of Ingush State University, Magas, Republic Of Ingushetia, Russia



**Abdusaid Abdumutalibovich Kurbanov** is a Student of Dagestan State Medical University, Makhachkala, Republic of Dagestan, Russia



**Silviya Grayrovna Arzumanyan** is a Student of Rostov State Medical University, Rostov-on-Don, Russia

---