



## A New Technique in the Diagnosis and Treatment of Caries and Pulpitis

Dinara Albertovna Chechenova<sup>1</sup>, Zalina Georgievna Dzgoeva<sup>2\*</sup>, Madina Ruslanovna Mrikaeva<sup>2</sup>, Alina Muratovna Orsaeva<sup>3</sup>, Zalina Rasulovna Budaeva<sup>1</sup>, Sanita Mukhamedovna Gukemukhova<sup>4</sup>, Alina Olegovna Slanova<sup>2</sup>, Nadiia Alimovna Saidova<sup>3</sup>, Milana Arturovna Ashinova<sup>1</sup>, Julia Zurabovna Frieva<sup>2</sup>

<sup>1</sup> Kabardino-Balkarian State University named after H.M. Berbekov, Nalchik, Republic of Kabardino-Balkaria, RUSSIA.

<sup>2</sup> North Ossetian State Medical Academy, Vladikavkaz, Republic of North Ossetia-Alania, RUSSIA.

<sup>3</sup> Moscow State Medical and Dental University named after A. I. Evdokimov, Moscow, RUSSIA.

<sup>4</sup> Stavropol State Medical University, Stavropol, RUSSIA.

\*Corresponding Author (Tel: +79183500889, [ruslankalmykov777@yandex.ru](mailto:ruslankalmykov777@yandex.ru)).

Paper ID: 13A11T

Volume 13 Issue 11

Received 16 March 2022

Received in revised form  
03 July 2022

Accepted 15 July 2022

Available online 26 July  
2022

### Keywords:

Deep caries; Pulp; pulpitis; Preservation of damaged pulp; Photocomposite; Trioxident; Carious cavity; Periodontal fissure.

### Abstract

Dental caries is one of the most common diseases of the oral cavity, this problem is relevant all over the world and has a significant impact on the quality of human life. This article describes a clinical case of deep caries treatment in a 47-year-old patient. The treatment was carried out with the use of the drug "Trioxident". Indications for the use of the material are an accidentally opened tooth cavity during the treatment of a carious cavity, pulp hyperemia, and other forms of "reversible pulpitis" with mild complaints and electrodontometry readings of no more than 25 mica. Contraindications to the use of this method with a specified diagnosis include acute diffuse pulpitis, chronic and exacerbation of chronic forms of pulpitis, and periodontal fissure enlargement by radiograph.

**Discipline:** Medicine, Dentistry.

©2022 INT TRANS J ENG MANAG SCI TECH.

### Cite This Article:

Chechenova, D.A., Dzgoeva, Z.G., Mrikaeva, M.R., Orsaeva, A.M., Budaeva, Z.R., Gukemukhova, S. M., ... Frieva, J.Z. (2022). A New Technique in the Diagnosis and Treatment of Caries and Pulpitis. *International Transaction Journal of Engineering, Management, & Applied Sciences & Technologies*, 13(11), 13A11T, 1-7. <http://TUENGR.COM/V13/13A1T.pdf> DOI: 10.14456/ITJEMAST.2022.230

## 1 Introduction

Dental caries is one of the most common diseases of the oral cavity. This problem is relevant all over the world and has a significant impact on the quality of human life [1, 2]. Caries is a progressive disease that causes demineralization, thereby weakening immune barriers and

destroying the hard tissues of teeth [3]. In the absence of timely diagnosis and treatment at the initial stages, caries spreads deep layers of enamel and dentin [5, 6]. Deep carious lesions cause inflammation of the pulp, affecting the periapical region [7]. Based on the presence of this problem, an active study of the prevalence of caries in different countries, depending on age, is being conducted.

In clinical practice, the problem of preserving the damaged pulp of the tooth confronts the doctor even when the pulp chamber remains unopened during the treatment of deep carious lesions of the dentin, and there are no clinical signs of degenerative changes in the pulp and periapical tissues.

It is known that the pulp performs plastic, protective, trophic and sensory functions [7-8]. One of the most important functions is plastic, characterized by the systemic formation of dentin. Even in the period after teething, the pulp continues to produce dentin [10]. Reparative dentin can also be obtained in response to physical or chemical damage [11]. At the same time, odontoblasts retain their properties inside the newly formed tissue. Also, to maintain the viability of the pulp, liquid and nutrients are transported into it [12-14].

## 2 Literature Review

There is an equally urgent problem today: deep caries. Deep caries is a pathological process in which the lesion of the periculpal dentin occurs [15]. In this disease, the pulp is constantly exposed to the environment: microbial toxins, temperature changes, mechanical trauma, and intoxication with filling materials [16-17]. After various impacts, pulp cells have the internal ability to regenerate, differentiate into odontoblasts and produce various proteins of the dentin matrix during recovery [14, 17]. When the pathological process of exposure is eliminated before the pulp is damaged, the regeneration process begins, and collagen synthesis occurs in this phase [18]. Thus, the pulp has significant regenerative potential, and an inflammatory reaction in pulp tissues does not always lead to irreversible damage to cells, which is confirmed in a number of studies [9, 19-20].

## 3 Method

A clinical case of a biological method of deep caries treatment with preservation of pulp vital activity is presented below.

A 47-year-old patient complained of pain in the 3.6 tooth when eating solid food, also, a reaction to temperature stimuli was observed, the patient notes the buildup of food between the 3.6 and 3.7 teeth, the pain appeared a month ago.

Objectively: there is a deep carious cavity on the chewing surface 3.6, probing is painful along the bottom of the cavity, the reaction to cold is painful, short-term. In this clinical situation, we observe an extensive defect located very close to the pulp chamber.

It is known that in order to quickly restore the vital activity of the pulp after a short-term inflammatory reaction, it is necessary to take into account the bacterial factor [7, 17]. As a dressing, it is usually recommended to use calcium hydroxide, which has:

- 1) bactericidal action; coagulation and dissolution of necrotic tissues;

- 2) prevents bone resorption;
- 3) induces the formation of an osteocement apical barrier;
- 4) stimulates the formation of a dentine bridge (with direct pulp coating).

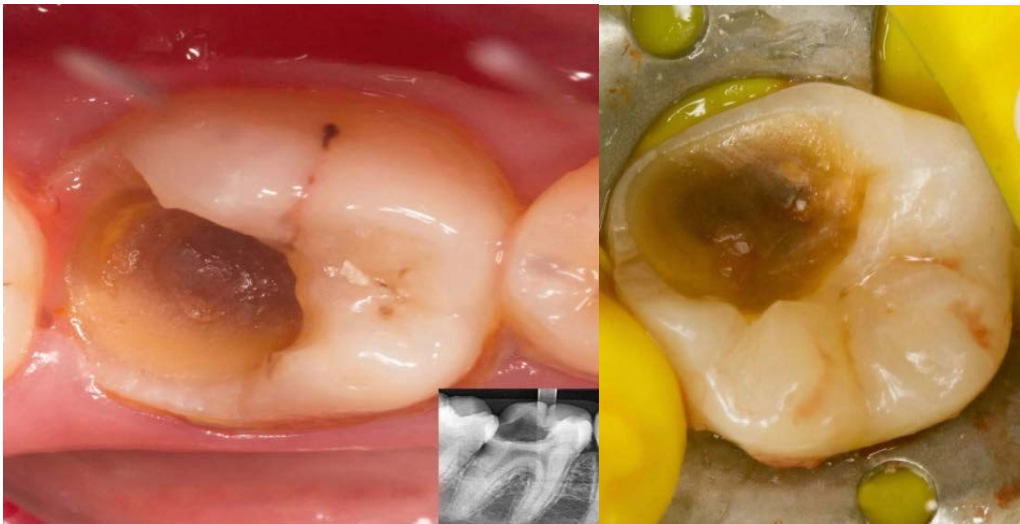For the first time, these drugs became widely used in the 30s of the XX century, thanks to Dr. Horman (Germany), who in his practice used "CALCYL" ("Calcil") with the composition: calcium hydroxide and Ringer's solution - for the biological treatment of pulp [3, 7].

### 3.1 Materials and Methods

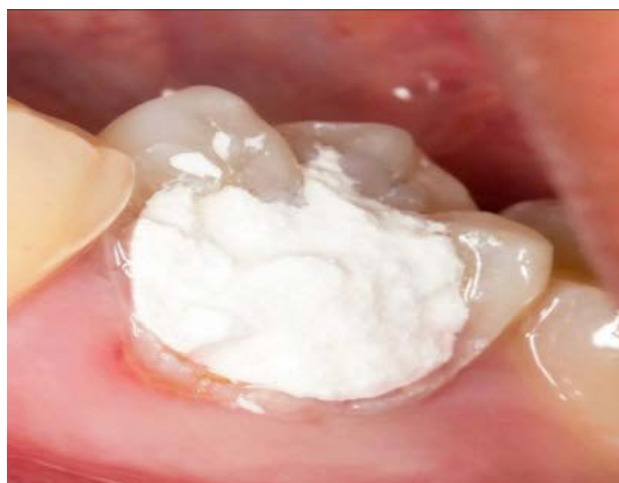Dental material "Trioxident" (VladMiVa, Russia), distilled water.

The method of treatment with the use of the drug "Trioxident" included the following stages.

After anesthesia of the causal tooth, instrumental treatment of the carious cavity was carried out (figure 1), drug treatment with antiseptics in low concentrations (0.06% solution of chlorhexidine bigluconate).



**Figure 1.** Instrumental treatment of the causal tooth of the carious cavity



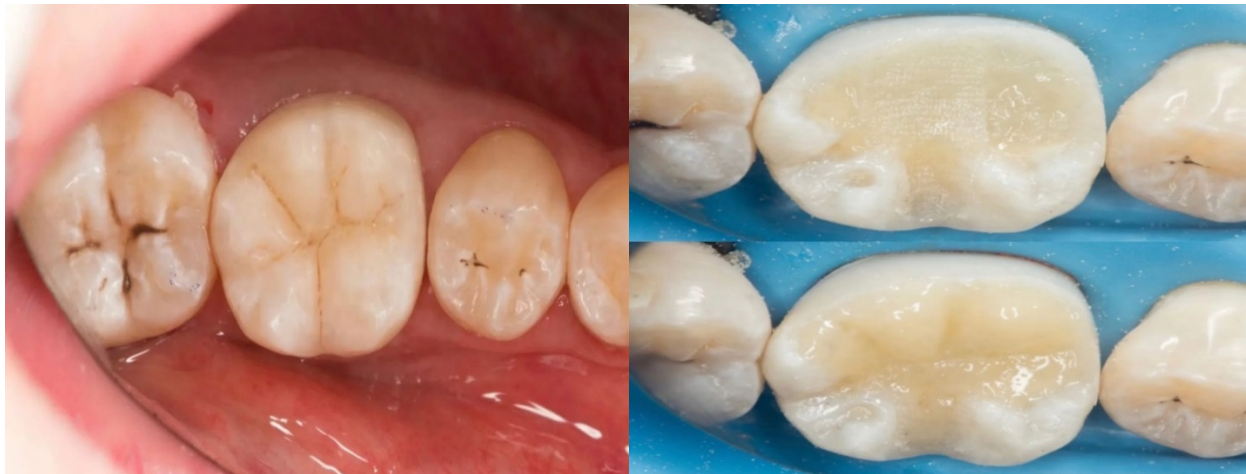**Figure 2.** Temporary seal made of Vitremer material

Dental material "Trioxident" was mixed at room temperature 18-23 ° C on a dry plate with a dry clean plastic spatula in a powder/distilled water ratio of 3:1 for 30-40 seconds until a plastic paste was obtained.

Next, a thin layer (0.5 mm) was applied to the bottom of the carious cavity and pressed with a dry, tight, sterile cotton swab with a therapeutic pad made of "Trioxidant", making sure that the material did not get either on the mucous membrane or into the gingival furrow.

The material is cured within 10 minutes (final polymerization within 24 hours). The excess of the introduced material located outside the cavity was removed with boron. We finished the work by setting a temporary seal made of Vitremer material (Figure 2).

On the second visit (after 7-10 days), the electrical excitability of the pulp was monitored and, in the absence of negative dynamics, the restoration of the tooth crown was performed using a photocomposite (Figure 3).



**Figure 3.** Restoration of the tooth crown using a photocomposite.

The control examination was repeated after 1, 3, 6, 12 and 24 months with mandatory Electrodontodiagnostics and sighting radiography.

## 4 Results and Discussion

The criteria for the effectiveness of the biological method of pulpitis treatment using the drug "Trioxidant" at different stages of observation were:

- 1) the absence of complaints or the presence of a minor, short-term reaction to a temperature stimulus;
- 2) painless percussion;
- 3) data of targeted X-ray examination (determination of changes in periapical tissues);
- 4) the state of electrical excitability of the tooth pulp according to the indications of electrodontometry (should not exceed 10-15  $\mu\text{A}$ ). Evaluation of these indicators at all stages of follow-up indicated that positive dynamics and good treatment outcomes were achieved in the treatment of 21 teeth with a diagnosis of reversible pulpitis.

In three cases, the treatment outcomes were assessed by us as unsatisfactory. Complications manifested themselves in the form of spontaneous aching pains, increasing pain from irritants, pain when biting on a cured tooth (in 2 patients). One patient was diagnosed with pulp death - without any clinical signs and complaints from the patient. We noted this complication after 4-6



months according to the results of electrodontometry and X-ray examination (expansion of the periodontal gap). The causes of such complications, in our opinion, could be diagnostic errors, poorly performed mechanical and medical treatment of the carious cavity, or errors in applying a therapeutic bandage.

## 5 Conclusion

The use of the Trioxident material in the treatment of pulpitis by the biological method allows us to obtain positive results in 87.5% of cases (in 21 patients). The use of the material in the clinic does not cause difficulties both when kneading and when applying it into a properly prepared cavity. A necessary condition for the successful outcome of treatment is the competent informing of the patient about the direction of therapeutic measures. Indications for the use of the material are an accidentally opened tooth cavity during the treatment of a carious cavity, pulp hyperemia and other forms of "reversible pulpitis" with mild complaints and electrodontometry readings of no more than 25 mica. Contraindications to the use of this method with a specified diagnosis are: acute diffuse pulpitis, chronic and exacerbation of chronic forms of pulpitis, periodontal fissure enlargement by radiograph. Thus, the Trioxident material showed high efficiency and proved to be convenient to use. In all cases, positive dynamics was revealed during the observation period. Sealed packaging with a dosage of 0.5 g of powder in an amount of 10 sachets allows you to always have a sterile preparation ready for use, preserved at a temperature of 5-25 C. The working time of the Trioxident material is 10-15 minutes.


## 6 Availability of Data and Material

Data can be made available by contacting the corresponding author.

## 7 References

- [1] Kotsoeva GA, Esiev RK, Toboev GV, Zakaeva RS, Kulova AA, Tsokova LV, et al. Phytoadaptogenic Cocktail Use "Biorithm-E" In The Complex Treatment Of Odontogenic Inflammatory Diseases of The Maxillofacial Region. *Ann. Dent. Spec.* 2021;9(2):52-57. DOI: 10.51847/PyVv83OTGt
- [2] de Santana DA, Fonseca GF, Ramalho LMP, Rodriguez TT, Aguiar MC. Effect of low-level laser therapy ( $\lambda 780$  nm) on the mechanically damaged dentin-pulp complex in a model of extrusive luxation in rat incisors. *Lasers Med Sci.* 2017;32(9):1995-2004. DOI: 10.1007/s10103-017-2295-6.
- [3] Galabueva AI, Biragova AK, Kotsoyeva GA, Borukayeva ZK, Yesiev RK, Dzgoeva ZG, et al. Optimization of Modern Methods of Treating Chronic Generalized Periodontitis of Mild Severity. *Pharmacophore* 2020;11(1):47-51
- [4] Bjørndal L, Reit C, Bruun G, Markvart M, Kjaeldgaard M, Näsman P, Thordrup M, Dige I, Nyvad B, Fransson H, Lager A, Ericson D, Petersson K, Olsson J, Santimano EM, Wennström A, Winkel P, Gluud C. Treatment of deep caries lesions in adults: randomized clinical trials comparing stepwise vs. direct complete excavation, and direct pulp capping vs. partial pulpotomy. *Eur J Oral Sci.* 2010;118(3):290-7. DOI: 10.1111/j.1600-0722.2010.00731.x
- [5] Sadyrin E, Swain M, Mitrin B, Rzhepakovsky I, Nikolaev A, Irkha V, Yogina D, Lyanguzov N, Maksyukov S, Aizikovich S. Characterization of Enamel and Dentine about a White Spot Lesion:

- [6] Dammaschke T. The history of direct pulp capping. *J Hist Dent*. 2008;56(1):9-23.
- [7] Ayivi R, Ibrahim S, Colleran H, Silva R, Williams L, Galanakis C, Fidan H, Tomovska J and Siddiqui SA. COVID-19: human immune response and the influence of food ingredients and active compounds. *Bioactive Compounds in Health and Disease*. 2021;4(6):100
- [8] Fusayama T. Two layers of carious dentin; diagnosis and treatment. *Oper Dent*. 1979;4(2):63-70.
- [9] Phillips RW, Crim G, Swartz ML, Clark HE. Resistance of calcium hydroxide preparations to solubility in phosphoric acid. *J Prosthet Dent*. 1984;52(3):358-60. DOI: 10.1016/0022-3913(84)90444-x
- [10] Smith AJ, Lumley PJ, Tomson PL, Cooper PR. Dental regeneration and materials: a partnership. *Clin Oral Investig*. 2008;12(2):103-8. DOI: 10.1007/s00784-008-0189-5
- [11] Blinov AV, Nagdalian AA, Povetkin SN, Gvozdenko AA, Verevkina MN, Rzhepakovsky IV, Lopteva MS, Maglakelidze DG, Kataeva TS, Blinova AA, Golik AB, Osipchuk GV, Shariati MA. Surface-Oxidized Polymer-Stabilized Silver Nanoparticles as a Covering Component of Suture Materials. *Micromachines*. 2022; 13(7):1105. DOI: 10.3390/M113071105
- [12] Bergenholtz G. Evidence for bacterial causation of adverse pulpal responses in resin-based dental restorations. *Crit Rev Oral Biol Med*. 2000;11(4):467-80. DOI: 10.1177/10454411000110040501.
- [13] Gvozdenko, A.A., Blinov, A.V., Slyadneva, K.S. et al. X-Ray Contrast Magnetic Diagnostic Tool Based on a Three-Component Nanosystem. *Russ J Gen Chem* 2022; 92, 1153–1160. DOI: 10.1134/S1070363222060305
- [14] Kuposova N, Eriksen HM, Widström E, Handegård BH, Pastbin M, Kuposov R. Caries prevalence and determinants among 12-year-olds in North-West Russia and Northern Norway. *Stomatologija*. 2013;15(1):3-11.
- [15] Domenyuk DA, Zelensky VA, Rzhepakovsky IV, Anfinogenova OI, Pushkin SV. Application of laboratory and x-ray general studies un early diagnostics of metabolic disturbances of bone tissue in children with autoimmune diabetes mellitus. *Entomology and Applied Science Letters*. 2018 1;5(4):1-2.
- [16] Levin LG, Law AS, Holland GR, Abbott PV, Roda RS. Identify and define all diagnostic terms for pulpal health and disease states. *J Endod*. 2009 Dec;35(12):1645-57. DOI: 10.1016/j.joen.2009.09.032.
- [17] Maltz M, Jardim JJ, Mestrinho HD, Yamaguti PM, Podestá K, Moura MS, de Paula LM. Partial removal of carious dentine: a multicenter randomized controlled trial and 18-month follow-up results. *Caries Res*. 2013;47(2):103-9. DOI: 10.1159/000344013.
- [18] Orsaeva AT, Tamrieva LA, Mischvelov AE, Osadchiy SS, Osipchuk GV, Povetkin SN, Simonov AN. Digital clinic “smart ward. *Pharmacophore*. 2020;11(1):142-146
- [19] Massler M, Pawlak J. The affected and infected pulp. *Oral Surg Oral Med Oral Pathol*. 1977 Jun;43(6):929-47. DOI: 10.1016/0030-4220(77)90086-x.




**Dinara Albertovna Chechenova** is a student of Kabardino-Balkarian State University named after H.M. Berbekov, Nalchik, Republic of Kabardino-Balkaria, Russia



**Zalina Georgievna Dzgoeva**, holding a Doctor of Medical Sciences, is an Associate Professor of the Department of Dentistry of the North Ossetian State Medical Academy, Vladikavkaz, Republic of North Ossetia-Alania, Russia



**Madina Ruslanovna Mrikaeva** is an Associate Professor of the Department of Dentistry of the North Ossetian State Medical Academy, Vladikavkaz, Republic of North Ossetia-Alania, Russia.




**Alina Muratovna Orsaeva** is a Student of Moscow State Medical and Dental University named after A. I. Evdokimov, Moscow, Russia



**Zalina Rasulovna Budaeva** is a student of Kabardino-Balkarian State University named after H.M. Berbekov, Nalchik, Republic of Kabardino-Balkaria, Russia




**Sanita Mukhamedovna Gukemukhova** is a Student of Stavropol State Medical University, Stavropol, Russia



**Alina Olegovna Slanova** is a Student of North Ossetian State Medical Academy, Vladikavkaz, Republic of North Ossetia-Alania, Russia



**Nadiia Alimovna Saidova** is a Student of Moscow State Medical and Dental University named after A. I. Evdokimov, Moscow, Russia



**Milana Arturovna Ashinova** is a student of Kabardino-Balkarian State University named after H.M. Berbekov, Nalchik, Republic of Kabardino-Balkaria, Russia



**Julia Zurabovna Frieva** is a Student of North Ossetian State Medical Academy, Vladikavkaz, Republic of North Ossetia-Alania, Russia