



Anatomical and Topographic Features of the Major Masticatory Muscle in Sheep

N.A. Slesarenko^{1*}, E.O. Oganov¹, V.A. Ivantsov¹, E.O. Shirokova¹

¹ FSBEI HE MSAVMandB - MVA named after K.I. Scriabin, Moscow, RUSSIA.

*Corresponding author (Email: slesarenko2009@yandex.ru).

Paper ID: 13A1N

Volume 13 Issue 1

Received 12 August 2021
Received in revised form 23 October 2021
Accepted 29 October 2021
Available online 15 November 2021

Keywords:

Chewing muscles; Small cattle; Sheep head; Masseter muscle.

Abstract

The article provides information about the anatomical and topographic features of the major masticatory muscle in sheep. The research was carried out on the basis of the Department of Animal Anatomy and Histology named after Professor A.F. Klimov MSAVMandB - MVA named after K.I. Scriabin on 10 animals using the method of fine anatomic dissection, followed by functional analysis of the studied structures and skeletotopic projection of areas for fixing parts of muscles. The biomechanical capabilities of the jaw apparatus and the transformative effect of the chewing function on the head bony frame in sheep have been established. The data obtained are basic for deciphering the biomechanics of the temporomandibular joint in small cattle.

Disciplinary: Animal and Biology Sciences, Biomechanics, Veterinary Sciences.

©2022 INT TRANS J ENG MANAG SCI TECH.

Cite This Article:

Slesarenko, N. A., Oganov, E. O., Ivantsov, V.A., Shirokova, E.O. (2022). Anatomical and Topographic Features of the Major Masticatory Muscle in Sheep. *International Transaction Journal of Engineering, Management, & Applied Sciences & Technologies*, 13(1), 13A1N, 1-6. <http://TUENGR.COM/V13/13A1N.pdf> DOI: 10.14456/ITJEMAST.2022.14

1 Introduction

As is known, the masticatory apparatus in ruminants is capable of performing various types of movements: closing, opening, abduction, adduction. Among the mandibular clamps, the major masticatory muscle makes up 50% of their total mass. Its two-layer structure, especially pronounced in herbivores, with alternating reduction of the surface and deep parts, it allows for lateral, millstone-like movements when grinding feed (Slesarenko and Sharovatova, 2014; Tuganov, 2000; Paiva Neto et al., 2018; Herring et al. 2001; Pares-Casanova et al., 2018; Herring, 2007; Turnbull, 1970).

In representatives of other taxonomic groups, the authors distinguish the superficial, deep, intermediate (cranio-dorsal) parts in the major masticatory muscle, as well as the temporal dorsal part (Sovetbek, 2021; Slesarenko et al., 2021; Kuznetsov, 1994; Slesarenko and Sharovatova, 2014; Herring et al., 2001; Herring, 2007; Turnbull, 1970). Nevertheless, in the available literature, there is practically no information on the functional anatomy and topography of this muscle in small cattle (Slesarenko and Sharovatova, 2014; Tuganov, 2000; Pares-Casanova et al., 2018). The purpose of this research is to establish anatomical and topographic features of the major masticatory muscle in sheep.

2 Material and Methods of Research

Sectional material was examined - heads (n=10) selected from sexually mature (1.5 years old) sheep of the Romanov breed. Age was determined by the method of Sh. Korneven and F.-K. Lesbr (2011). Methods of fine anatomical dissection were used, followed by functional analysis of the studied structures and skeletotopic projection of areas for fixing parts of muscles (Slesarenko, 2018).

3 Research results

It was found that under the scalp there is its superficial fascia, which is a continuation of the superficial fascia of the neck. It is divided, as known, into the surface and deep sheets. In the area of the sheep's head, the subcutaneous muscle of the head is enclosed between its leaves (Figure 1), located ventrally to the zygomatic. In the orbit area, the superficial fascia tightly fuses with the skin, the corneal processes of the frontal bone, the lateral surface of the nose, lips and nostrils.

The deep fascia is located under the superficial fascia (Figure 1-a, 2-b). Between the sheets of the superficial and deep fascia, the zygomatic muscle and the lower eyelid depressor are enclosed. The deep fascia in this area is attached to the zygomatic arch, the skin of the lower eyelid and further, in the rostral direction, arched extends to the facial cristae. Under it, there is the subfascial fatty tissue, and under it, there is the major masticatory muscle (Figure 2).

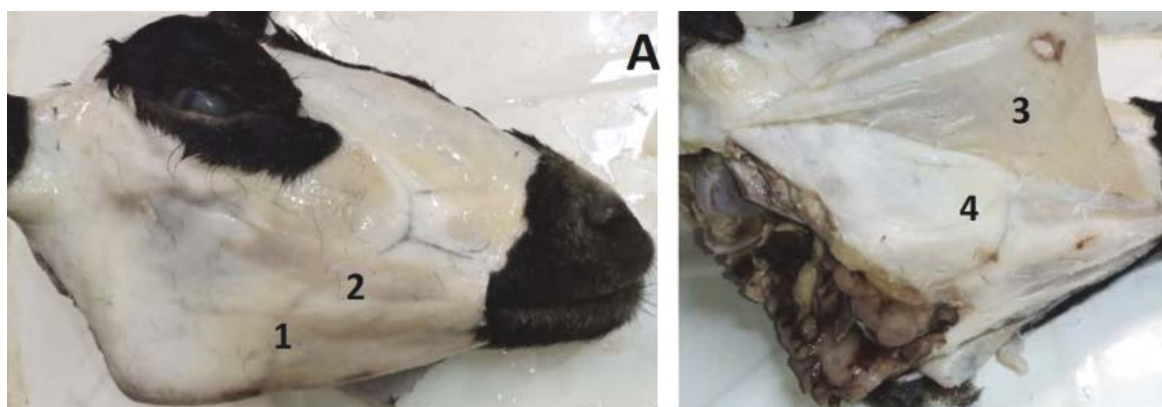


Figure 1: Gross specimen of the sheep's head: 1- subcutaneous muscle of the head; 2- zygomatic muscle; 3- superficial fascia of the head; 4- deep fascia of the head.

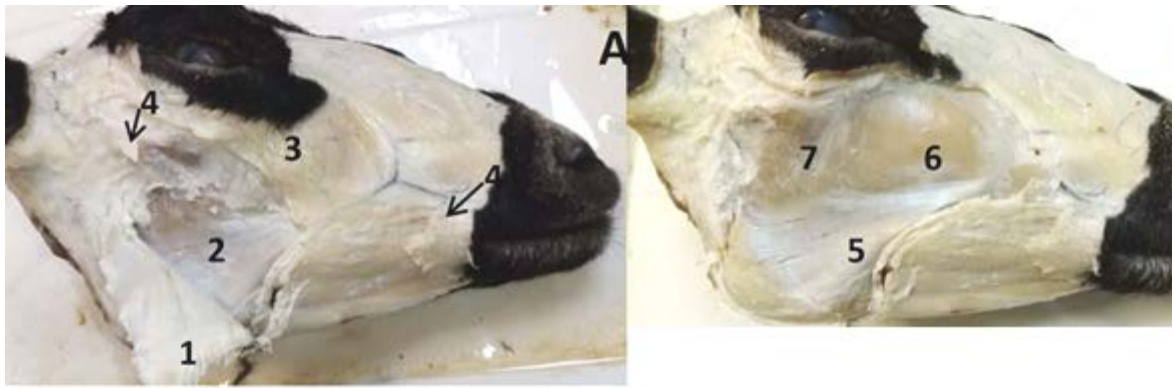

Figure 2: Gross specimen of the sheep's head: a- deep fascia of the head was opened, b- after removal of the deep fascia: 1- deep fascia; 2- major masticatory muscle; 3- lower eyelid depressor; 4- zygomatic muscle (cut off); 5- ventral part, 6- posterior dorso-rostral part and 7- dorso-caudal part of the superficial masticatory muscle.

In our study, we concluded that the major masticatory muscle in sheep is a complex muscle represented by 6 muscles that form three layers - superficial, intermediate and deep. They differ in their external shape, structure, direction of muscle fibers and attachment points. Thus, the surface layer is represented by 3 parts (Figure 2).

1. *The ventral part* is triangular in shape, starting from the facial cristae with a powerful tendon, which in the caudal and caudo-ventral direction diverges in flabelliform to the edge of the lower jaw angle up to the mandibular notch, forming a tendon mirror on the muscle surface (Figure 2-b-5). The myogaster is well developed in the ventro-caudal part, in the region of the mandibular fossa (Figure 3). The aboral end of the muscle is attached to the corner of the mandibular bone, which in the form of a narrow platform continues to the vascular tenderloin (Figure 3 (5- bare area)).

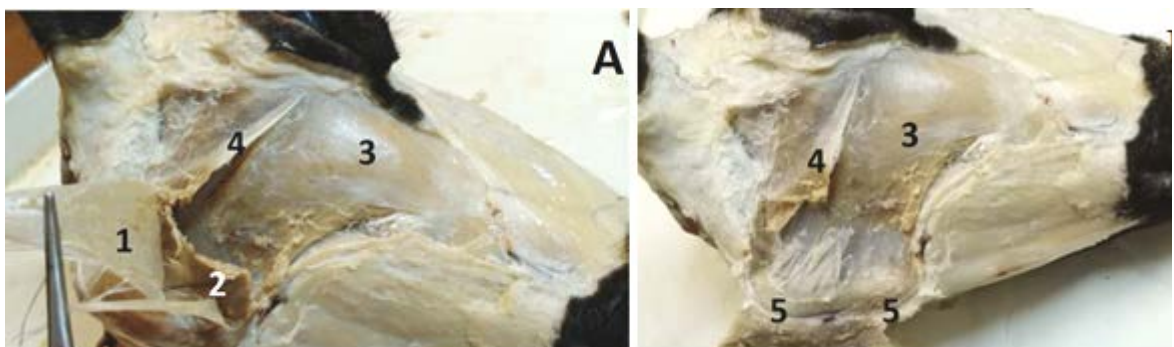


Figure 3: Gross specimen of the sheep's head. Ventral part of the superficial masticatory muscle: 1- tendon mirror of the ventral part of the muscle (the muscle is cut off from the facial cristae); 2- myogaster of the ventral part; 3- dorso-rostral part and 4- dorso-caudal part of the superficial masticatory muscle; 5- area for attaching the ventral part of the superficial masticatory muscle.

2. *The dorso-caudal part* in the form of a trapezoid is located caudal to the dorso-rostral and above the ventral part of the superficial masticatory muscle (Figure 3, 4), occupying the upper-posterior surface of the lower jaw branch. Its proximal end is attached by a flat tendon, starting from the middle part of the zygomatic arch to the middle part of the zygomatic process of the

temporal bone, while its anterior edge is tendon-like to half of the muscle. The muscle fibers are directed caudo-ventrally, the anterior-lower part of the muscle merges with the ventral part of the surface layer for a short distance. Most of the dorso-caudal part is attached with its lower end to the caudal edge of the mandibular bone branch, above the ventral part of the muscle (Figure 4 (2.2- cut off)). There is an intermediate layer under it.

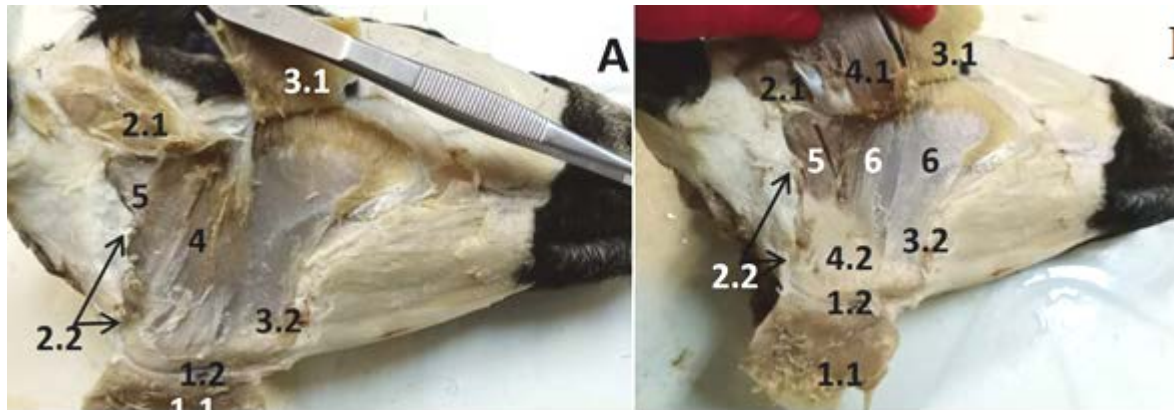


Figure 4: Gross specimen of the sheep's head. The surface layer muscles are abducted (A), the intermediate part is additionally abducted (B): 1.1- ventral superficial muscle, 1.2- area of its distal attachment; 2.1- dorso-caudal muscle, 2.2- place of its attachment; 3.1- myogaster of the superficial dorso-rostral muscle; 3.2- its tendon part and the place of attachment; 4, 4.1- intermediate muscle, 4.2- distal area for its attachment; 5- temporal dorsal muscle; 6- deep dorso-rostral muscle.

3. *The superficial dorso-rostral part* (muscle) (Figure 3 (3), 4 (3.1, 3.2)) is attached in arch-shape with the dorsal end to the anterior half of the zygomatic arch and the facial line extending from the zygomatic arch to the facial cristae. The dorsal part of the muscle is more fleshy, it narrows somewhat to the ventral end and is attached by a wide tendon (the tendon forms the medial surface of the muscle) to a narrow area on the mandibular bone slightly above the area for the ventral part of the muscle, more caudal to the vascular notch. The direction of the muscle fibers of this part is dorso-ventral.

The intermediate layer is represented by one part located under the dorso-caudal and posterior dorsal parts of the ventral superficial muscle (Figure 4 (4, 4.1, 4.2)). Its rostral edge borders with the posterior edge of the superficial dorso-rostral muscle. It has a rectangular shape, muscle fibers are oriented dorso-ventrally. The dorsal end of the muscle is attached by a flat tendon to the lower surface of the middle part of the zygomatic arch, under the place of attachment of the dorso-caudal part of the muscle. The ventral end of the muscle (fleshy) occupies an extensive area in the mandibular fossa, above the area for the ventral part (Figure 4, B-4.2).

The deep layer of the major masticatory muscle is represented by two parts - deep dorso-rostral and temporal dorsal. 1. *The deep dorso-rostral part*, in comparison with other muscles of this muscle complex, is the most extensive. It is located under the superficial dorso-rostral and along its caudal edge it is covered by the intermediate part of the muscle.

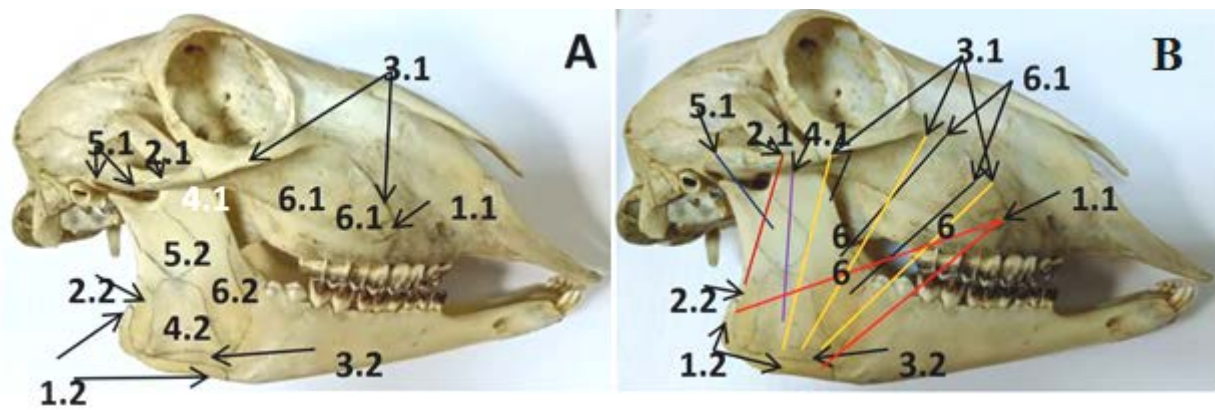


Figure 5: Skeletotopic markings of parts of the major masticatory muscle in sheep: 1.1, 1.2- points of fixation of the ventral part of the superficial masticatory muscle; 2.1, 2.2- points of fixation of the dorso-caudal part of the superficial masticatory muscle; 3.1, 3.2- points of fixation of the superficial dorso-rostral muscle; 4.1, 4.2- points of fixation of the intermediate muscle; 5.1, 5.2- points of fixation of the temporal dorsal muscle; 6.1, 6.2 - points of fixation of the deep dorso-rostral muscle. The lines on the bones indicate the boundaries of the attachment areas of the parts of the major masticatory muscle (A), the colored lines indicate the direction of the muscle fibers (B).

The deep part of the muscle is attached to 2/3 of the anterior part of the zygomatic arch (in the recess of its lower surface), and then the arched facial line reaching the facial cristae and the area below the facial line (Figure 4 - B (6)). Muscle fibers converge to the anterior edge of the branch and the lateral surface of the mandible (at the level of the vascular notch), where they attach to the mandibular bone (Figure 5 (A - 6.1, 6.2, B- 6, 6.1)). Thus, the direction of the muscle fibers from the ventral tendon to the dorsal tendon is flabelliform. With its front edge, it covers the caudal part of the buccinator muscle.

2. *The temporal dorsal* (temporomandibular) part is small, nevertheless, fleshy (Figure 4 (A, B-5)), on the branch of the lower jaw it is covered by an intermediate muscle. Muscle fibers are directed from the posterior part of the zygomatic arch to the proximal part of the mandibular bone branch in the ventro-rostral direction (Figure 5 (A, B - 5.1, 5.2)).

4 Conclusion

Thus, the major masticatory muscle in sheep is complex, that is, it is a complex combination of various parts having a three-layer structural organization, a special macroarchitecture, structural composition, orientation of muscle fibers, skeletotopic markings for fixing parts. Specific features of the orientation of muscle fibers provide versatile movements in the temporomandibular joint, mainly the closing of the jaws (ventral part, dorso-caudal, superficial and deep dorso-rostral, and intermediate muscles). Nevertheless, the direction of the muscle fibers of the temporal dorsal, in combination with the intermediate and dorsal caudal parts of the muscle suggests the abduction of this joint. Ventro-rostral orientation of the muscle fibers of the temporal dorsal part of the muscle in combination with the digastric muscle can contribute to the opening of the jaws.

It is found that the biomechanical capabilities of the jaw apparatus are determined by the topical features and morphometric indicators of the masticatory muscles. The transformative effect of the chewing function on the bony frame of the sheep head has been established. Correlations

between the action of muscles and movements of the lower jaw contribute to craniofacial morphology.

5 Availability of Data and Material

Data can be made available by contacting the corresponding author.

6 References

- Anarbek uulu Sovetbek. (2021). Topographic anatomy of the cerebral and maxillary region of the head of the Kyrgyz Sighthound. Abstract of Dissertation Cand. Biol. Sciences, Bishkek, 19 p.
- Herring Susan W. et al. (2001). Jaw muscles and the skull in mammals: the biomechanics of mastication. *Comparative Biochemistry and Physiology Part A*. 131, 207-219.
- Herring Susan W. (2007). Masticatory muscles and the skull: a comparative perspective. *Arch Oral Biol*. 52(4), 296-299.
- Korneven Sh. And F.-K. Lesbr. (2011). Age recognition by teeth and epithelial derivatives: Horses, cows, dogs...- 3rd ed. Moscow: Book House "Librocom", 256 p.
- Kuznetsov S.I. (1994). Development of chewing muscles, lower jaw and teeth in silver-black foxes in the postnatal period of ontogenesis and domestication changes in the chewing apparatus: abstract. dis.... Cand. Biol. Sciences. Moscow, 18 p.
- Paiva Neto A.O. et al. (2018). Biomechanical analysis of the masticatory movement before and after adjusting dental occlusion in equine. *Arq. Bras. Med. Vet. Zootec*. 70(1), 6-12.
- Pares-Casanova P.M. et al. (2018). Mastication in goats shows a chewing side preference. *Anim Husb Dairy Vet Sci*. 2(1), 1-3.
- Slesarenko N.A. et al. (2021). Anatomy of a dog. Somatic systems: textbook. St. Petersburg: Lan, 96 p.
- Slesarenko N.A. (2018). Methodology of scientific research. St. Petersburg: Lan, 268 p.
- Slesarenko N.A. and Sharovatova A.A. (2014). Comparative anatomical and functional characteristics of the masticatory muscle group in animals. *Bulletin of the Voronezh State Agrarian University*. 1-2(40-41), 125-130.
- Tuganov M.N. (2000). The jaw apparatus of domestic sheep of the Karachay and North Caucasian breeds in postnatal ontogenesis. Abstract of Dissertation Cand. Biol. Sciences, Stavropol, 21p.
- Turnbull William D. (1970). Mammalian masticatory apparatus. University of Illinois Urbana-Champaign. 356p.



Slesarenko Natalya Anatolyevna is Head of the Department, Doctor of Biological Sciences, Professor Scriabin. Her scientific interests are Structural and Functional Characteristics and Adaptive-Compensatory Mechanisms of Somatic, Visceral and Integrating Systems in Animals



Oganov Eldiyar Ormonovich is an Associate Professor, He is a Candidate of Veterinary Sciences, Associate Professor Scriabin. His scientific interests are Morphofunctional Changes in the Body of Poultry, Morphological Features of the Muscular System of Ruminants



Ivantsov Vyacheslav Alekseevich is an Associate Professor of the Department, He is a Candidate of Biological Sciences Scriabin. His scientific interests are Morphological Features of the Structural Organization of the Head Region in Various Animal Species.



Dr. Shirokova Elena Olegovna is an Associate Professor of the Department. She holds a Ph.D. Scriabin. Her scientific interests are Morphological Features of the Structural Organization of the Knee Joint in Various Animal Species and Risk Factors for the Development of Damage.